



# JOURNAL OF CLINICAL CHIROPRACTIC PEDIATRICS



VOLUME 13 • NO. 1 • JUNE 2012

PUBLICATION OF THE COUNCIL ON CHIROPRACTIC PEDIATRICS  
INTERNATIONAL CHIROPRACTORS ASSOCIATION

# JCCP JOURNAL OF CLINICAL CHIROPRACTIC PEDIATRICS

---

## EDITORS

**Sharon Vallone, DC, FICCP**

**Cheryl Hawk, DC, PhD**

---

## EDITORIAL REVIEW BOARD

**Marion Willard Evans, Jr.,**

**DC, PhD, MCHES**

Texas Chiropractic College, Pasadena, Texas

**Peter N. Fysh, DC, FICCP**

San Jose, California

**Alison K. Hazelbaker, MA, PhD, IBCLC**

Columbus, Ohio

**Anupama Kizhakkeveetil,**

**BAMS (Ayurveda), MAOM, Lac**

Southern California

University of Health Sciences

Whittier, California

**Dana J. Lawrence, DC, MMedEd, MA**

Palmer College of Chiropractic

Davenport, Iowa

**Robert A. Leach, DC, MS, CHES**

Starkville, Mississippi

**Maxine McMullen, DC, FICCP**

Port Orange, Florida

**Stephanie O'Neill-Bhogal, DC, DICCP**

Palmer College of Chiropractic

Davenport, Iowa

**Mart T. Pfefer, RN, MS, DC**

Cleveland College of Chiropractic

Overland Park, Kansas

**Katherine A. Pohlman, DC, MS, DICCP**

Palmer Center of Chiropractic Research

Davenport, Iowa

**Molly Rangnath, MA**

Falls Church, Virginia

**Richard Strunk, DC, MS**

Cleveland College of Chiropractic

Overland Park, Kansas

**Lora Tanis, DC, DICCP**

Hewitt, New Jersey

**Meghan Van Loon, PT, DC, DICCP**

New York College of Chiropractic

Seneca Falls, New York



The Journal of Clinical Chiropractic Pediatrics (JCCP) is the official peer-reviewed journal of the Council on Chiropractic Pediatrics, 6400 Arlington Boulevard, Suite 800, Falls Church, Virginia 22042, U.S.A. Printed and mailed in Virginia, U.S.A.

Copyright by the Council on Chiropractic Pediatrics. All rights reserved. Reproduction or translation of any part of this work beyond that permitted by Section 107 or 108 of the United States Copyright Law without permission of the copyright owner is unlawful. Printed in the United States.

**Editorial Correspondence:** Editorial correspondence should be sent to the Editor, JCCP, ICA Council on Chiropractic Pediatrics, 6400 Arlington Boulevard, Suite 800, Falls Church, Virginia 22042, U.S.A. Email: [peditriaticscouncil@chiropractic.org](mailto:peditriaticscouncil@chiropractic.org) or [svallonedc@aol.com](mailto:svallonedc@aol.com)



## TABLE OF CONTENTS

# JCCP JOURNAL OF CLINICAL CHIROPRACTIC PEDIATRICS

VOLUME 13, NUMBER 1

JUNE, 2012

<b>Editorial</b> .....	949
<i>Sharon Vallone, DC, FICCP</i>	
<b>Changing Trends in Puberty: Implications for Chiropractic Practitioners</b> .....	951
<i>Navine Haworth, DC, GCTTL, Sharon Gordon BAppSc(ClinSc)/BChiroSc, DICCP and Linda Jones, RN, RM, PhD</i>	
<b>An Investigation of Musculoskeletal Dysfunction in Infants Including a Case Series of KISS Diagnosed Children</b> .....	958
<i>Josefa Langkau and Joyce Miller, DC, DABCO, FCC(UK), FEAC, FACO(US)</i>	
<b>Recognition of Perinatal Stroke in a Chiropractic Practice: Case Report and Clinical Challenges Related to a Late Diagnosis</b> .....	968
<i>Christine Bourdeau, DC</i>	
<b>Chiropractic Management of Adductor Muscle Strain</b> .....	976
<i>Stephanie Willis, BAppSc(ClinSc)/BChiroSc, DICCP, CCWP</i>	
<b>Resolution of Delayed Motor Milestones and Abnormal Primitive Reflexes in an 8-Month-Old Full Term Infant Following Chiropractic Care</b> .....	980
<i>Donna M. Quezada, DC, BS, DICCP, DIBCN and Andrea Haan DC, MS</i>	
<b>Effects of Chiropractic Treatment in a 10-Year-Old Female Suffering from Chronic Constipation</b> .....	987
<i>Nancy Mayrand, DC</i>	
<b>Management of a 9-Year-Old Male with Encopresis and Chronic Constipation</b> .....	990
<i>Jennifer Brocker, DC and C. J. Woslander, DC</i>	
<b>Abstracts of Interest</b> .....	995



### PUBLISHING OFFICES:

ICA COUNCIL ON CHIROPRACTIC PEDIATRICS  
6400 Arlington Boulevard, Suite 800  
Falls Church, Virginia 22042 U.S.A.

Phone: 703-528-5000  
Fax: 703-351-7893

# JCCP JOURNAL OF CLINICAL CHIROPRACTIC PEDIATRICS

The *Journal of Clinical Chiropractic Pediatrics* welcomes original and scholarly manuscripts for peer-review and consideration for publication. Topics must pertain to the field of pediatrics which includes pregnancy and adolescence. Manuscripts should not have been published before or submitted to another publication.

## The following will be considered:

**Case Reports and Case Series** — presentations of individual or groups of cases deemed to be of interest to the professional and scholarly community.

**Pilot Studies or Hypothesis** — papers which, while very broad, present with a clear hypotheses and suggest a foundation for future, in-depth studies.

**Literature Reviews** — studies of existing papers and books presented with the intention of supporting and encouraging new and continuing study.

**Technical Descriptions** — reports of new analytical/diagnostic tools for assessment and delivery of care.

**Controlled, Large Scale Studies** — usually, but not necessarily, performed at a college or research facility. May be double-blinded.

**Commentaries** — presentations of opinion on trends within the profession or current events, pertaining to pediatric and adolescent chiropractic care.

## Guidelines for submission

All manuscripts are accepted purely for consideration. They must be original works and should not be under consideration by any other journal or publisher at the time of submission. They *must* be accompanied by a TRANSFER OF COPYRIGHT form, signed by all authors and by the employer if the paper is the result of a “work for hire.” It is understood that while the manuscript is under consideration it will not be sent to any other publication. In the case of multiple authors, a transmittal letter should designate one author as correspondent.

Manuscripts may be sent electronically (preferred) to [peditricscouncil@chiropractic.org](mailto:peditricscouncil@chiropractic.org), or on a CD (with one hard copy) by mail to JCCP, 6400 Arlington Boulevard,

Suite 800, Falls Church, Virginia 22042, USA. Manuscript should be in document style MS Word (or compatible) and unformatted.

**The first page** of the manuscript must contain:

1. The title of the paper
2. The first name, middle initial and last name of each author, with highest academic degree(s)
3. Names of departments and institutions to which the work should be attributed (if any)
4. Name, address and phone number of author responsible for correspondence
5. Source of funding (e.g. grants, self-funded, etc.)
6. Conflict of interest if any
7. Source of any support (e.g. equipment, organizations, individuals, etc.)

**The paper** must include an **abstract** or **summary**. This abstract/summary should state the purpose of the paper (objective), procedures, methods, main findings (results) and principal conclusions. Also, any key words or phrases that will assist indexers should be provided.

**References** must be cited for all materials derived from the works of other people and previously published works. Reference numbers must be assigned in the order of citation in the paper. References should follow the following format:

*From journals* —

Gorman JF. Automatic static perimetry in chiropractic. *J Manipulative Physiol Ther* 1993; 16(4):481-7.

*From books* —

Gatterman MI. Chiropractic management of spine related disorders. Baltimore: Williams & Wilkins; 1990.

**Tables** — Each table or figure should be on a separate page and not imbedded in the manuscript. If the table is from another publication, permission to publish must be granted and the publication acknowledged.

**Photographs** — Photographs should be scanned in grayscale at 300dpi with sharp contrast.

**Informed Consent** — If the research/study involves

---

experimental investigations performed on humans the manuscript must include a statement that informed consent was obtained from the individuals involved in the investigation.

**Patient Anonymity** — Patient names or any information that could identify a specific patient should be avoided. Photographs accompanying a manuscript must have a consent form signed by the individual or parent or guardian in the case of a minor. These are to include any requests for blocking faces, etc.

**Acknowledgements** — Any illustrations from other publications must be acknowledged. It is the author's responsibility to obtain written permission from the publisher and/or author for their use.

All manuscripts deemed appropriate for publication by the editor will be sent *blind* to at least two reviewers. If the manuscript is accepted, the author will be notified. If substantive changes are required, the paper will be returned to the author and the author must re-submit a clean copy of the revised manuscript. Author will be given a tentative

date for publication if accepted.

Manuscripts not accepted for publication will be returned to the author without comment.

### Summary of manuscript submission

1. Manuscript (digital in MS Word unformatted)
2. Illustrations/Diagrams (scanned at 100% in high resolution 300dpi)
3. Photographs (digital JPEG or TIFF 300dpi)
4. Transfer of copyright form signed by all authors.
5. Consent form for photographs (if applicable)
6. Letters of permission to use previously published materials (if applicable).
7. Cover letter from principal author (or author designed as correspondent) providing any special information regarding the paper that may be helpful in considering it for publication.
8. Digital files to be sent to [svallonedc@aol.com](mailto:svallonedc@aol.com).





## A Giant Step Forward for Chiropractic Pediatrics

Chiropractic Pediatrics has gone global! That's what this year has been about. The second round of Diplomates in Clinical Chiropractic Pediatrics (DICCPS) from the New Zealand College of Chiropractic graduated at a special commencement during the ICA Council on Chiropractic Pediatrics' Building Bridges Symposium on Chiropractic, Pediatrics & Research held in Sydney, Australia, June 20-22, 2012. It was an amazing conference where many countries and colleges were represented among the many speakers and attendees.

From the audience we listened to several "generations" of enthusiastic, dedicated leaders in our profession who generously shared their knowledge and expertise on topics ranging from positioning ourselves professionally through the media to reviewing the latest published research in our field. Talks were sprinkled with clinical cases to provide practice-based evidence from the speaker's daily clinical experiences. Workshops included tai kwon do for children on the autistic spectrum ("Neuron do") to adjustment techniques for the infant and the postpartum patient.

From the stage, speakers looked out at a room filled with attentive practitioners absorbing information to help them provide care to patients during pregnancy and after to pediatric years from infancy to school age/adolescence. They gave them cases to consider and demonstrated techniques to utilize and presented them with a summary of the research to back up why we do what we do.

Platform paper presentations and posters provided a peek at the individuals who are willing to do that extra work to help expand the knowledge base that we, as a profession, can refer to when confronted with a par-

ticular presentation in our own offices.

Why was this a momentous event? There have been many symposia but what was unique about this Symposium is that more chiropractors seem to be interested in expanding their knowledge base around the care of this important and vulnerable population. More important and significant is that they were present answering the call to accountability by voices outside of our profession with education, documentation and a self regulatory call for continued safe and ethical practices and evidence based research, while continuing to provide practice-based evidence as a tool to exercise good clinical judgment and provide quality clinical care.

The *Journal of Clinical Chiropractic Pediatrics* offers a venue to showcase and document literature for those in the chiropractic profession who care for or are interested in caring for pregnant women and children. It is also a resource for other professionals and academia interested in knowing more about this patient population.

As you peruse these pages and consider your own interesting, puzzling, even triumphant cases, consider documenting them and submitting them for possible presentation or publication. We need to send out a thousand paper lanterns to light the way for others who work alongside us and for those who come after.



**Sharon Vallone, DC, FICCP**

Co-Editor

*Journal of Clinical Chiropractic Pediatrics*





# Changing Trends in Puberty: Implications for Chiropractic Practitioners

Navine Haworth, DC, DICCP, GCTTL, Sharon Gordon, BAppSc(ClinSc)/BChiroSc, DICCP  
and Linda Jones, RN, RM, PhD

## ABSTRACT

**Objective:** The purpose of this paper is to review the changing ages of pubertal onset, and discuss how it may impact on chiropractic diagnosis and management in this pediatric population.

**Methods:** An open literature search was conducted, using scientific journal databases Pubmed, Science Direct, Medline, Proquest, and Medscape. An open internet search was also utilized.

**Discussion:** Puberty includes a range of events and the emergence of several secondary sexual characteristics. What has been considered the normal age ranges for puberty differ between gender (for females, 9-16 years of age and males, 13-15 years of age). Precocious puberty has been considered the onset of puberty prior to age 8 in girls, and 9 in boys. Recent studies however, have shown the onset of puberty earlier than expected, particularly in the female population. Precocious puberty may occur secondarily to pathologies such as endocrine disorders or central nervous system insults. Furthermore, with the onset of puberty, there is commonly a rapid growth period, which could potentially lead to a surprisingly 'early onset' for a number of orthopedic conditions. Chiropractors should be aware of emerging trends in the average age of onset of puberty and differentiate it from precocious puberty which may require referral.

**Conclusion:** It is important that chiropractic practitioners are aware of the changing trends, potential pathologies and underlying disorders that may contribute to an early pubertal onset. In addition, chiropractors need to be aware of the common orthopedic conditions presenting during periods of rapid growth and development. These may go undiagnosed if the practitioner is unaware of current adolescent age ranges.

**Key Words:** adolescent, chiropractic, pediatrics, precocious puberty

## Introduction

Observation of children in the western hemisphere reveals a trend in elementary school aged children reflecting developmental and sexual characteristics previously developmentally appropriate for a junior high or high school aged child. In contrast, anecdotal evidence from field trips to developing countries, reveals a noticeable difference in the development and appearance in many children. Children on assessment were noted to more closely resemble a young school aged child. What accounts for such a variation between an industrialized and developing country as to how a child develops? Many have suggested diet alone, particularly the Western diet, can account for these changing trends, resulting in earlier onset of pubarche

and menarche. The following will explore what theories account for these differences, and what these changes can mean for the chiropractor for diagnostic challenges, as well as management.

Before discussing the theories which could account for such differences, it is first important to define what is the normal range for adolescence. Much controversy and discussion has surrounded the issue of what is considered the normal age of onset. Although there is an established definition and sub-classifications for precocious puberty, researchers and pediatricians have encouraged that there be a review of the accepted definition.

## Definition of puberty

Puberty marks the onset of adolescence, and the emergence of several secondary sexual characteristics. In males, it has the sequence of increase in penis and testicular size, appearance of straight pubic hair, minor voice changes, spermatarche, kinky pubic hair, onset of maximum growth, growth of axillary hair, marked voice changes, growth of facial hair. In females, puberty commences with either thelarche (commencement of breast development) or pubarche (commencement of pubic hair growth). This can

---

**Navine Haworth, DC, DICCP, GCTTL**

Lecturer, RMIT University, Melbourne, Victoria, Australia  
navine.haworth@rmit.edu.au

**Sharon Gordon, BAppSc(ClinSc)/BChiroSc, DICCP**

Private practice, Warragul, Victoria, Australia  
sharon.gordon@rmit.edu.au

**Linda Jones, RN, RM, PhD**

Senior Lecturer, RMIT University, Melbourne, Victoria, Australia  
linda.jones@rmit.edu.au

be followed by axillary hair, widening of hips and height changes. Menarche occurs late in puberty.<sup>1</sup>

### Age range of pubertal onset

'Normal' ranges for menarche are from 9-15 years of age.<sup>2</sup> However, what has been considered the normal age ranges for puberty differ between sexes: for females, 9-16 years of age; and males, 13-15 years of age.<sup>3</sup> Precocious puberty has been considered prior to age 8 in girls, and 9 in boys. However, Kaplowitz et al (1999), suggested that breast and pubic hair development are occurring significantly earlier than suggested by our current guidelines, especially in African-American girls. Klein also further supports the notion that the norms for pubertal onset need reconsideration. In the 1999 study, Klein stated that the norms for pubertal development are based on 95% of the population or two Standard Deviations (2SD) below the mean age. Therefore, there is 2.5% possibility that a "normal" girl will have the onset of puberty prior to 8 years of age. The question posed has been whether puberty is truly precocious when it occurs between age 6 to 8, or is it simply on the outer limits of normal.<sup>4</sup> Many practitioners feel that these guidelines present a practical, evidence based approach.<sup>5</sup>

### Emerging trends of pubertal onset

What we once considered a child, is now considered a "tween", that is not quite a teen, and not quite a child, or the in between stage of childhood and adolescence.<sup>1</sup> Ages for tween is 8-12 years.<sup>6,7</sup> Many health practitioners might comment on the changes over the last decade on how the "twens" and "teens" seem to be developing much younger in comparison to several generations ago. Steingraber (2011) states that girls now menstruate for the first time, on average, a few months earlier than girls 40 years ago, but their breasts develop one or two years earlier.<sup>8</sup> This was a literature review of early onset of puberty in the U.S. One can deduce that the childhood of U.S. girls have been significantly shortened.<sup>8</sup> So, is a normal variation emerging to account for these differences, such as better health and nutrition, or are there many more factors, that are responsible for this trend? Styne (1991) suggested that the secular trend toward an earlier age of pubertal onset implicates health and nutrition as major determinants of the onset of sexual maturation.<sup>9</sup>

In response to a Pediatric Research in Office Settings network (PROS) study conducted in 1997, the Lawson Wilkins Pediatric Endocrine Society undertook a comprehensive review of this particular topic in regards to what is considered precocious puberty. The PROS 1997 study previously mentioned consisted of 17,077 females

being investigated for the normal onset of puberty across multiple pediatric clinics. The females that were assessed or this study were aged between 3-12 years of age. What they observed from this study was that pubertal onset tended to be earlier than expected. From the study population, the mean age of breast development in African American girls was 8.87 $\pm$ 1.93 year, and in caucasian females 9.96 $\pm$ 1.82year. This led to a different appreciation of the normal variation of age of pubertal onset. These authors concluded that females seen in a sample of pediatric practices from across the United States are developing pubertal characteristics at younger ages than currently used norms. They also deduced that practitioners may need to revise their criteria for referral of young girls with precocious puberty, with attention to racial differences. Therefore from this study, precocious puberty would be considered at prior to 5 years in African American females and prior to 6.3 years in Caucasian females, taking into account two standard deviations (SD) below average.<sup>10</sup>

Their findings are summarized below:

- Breast development before age 8 is precocious based on outdated studies. Until 1997, no data was available on pubertal staging in US girls that could have documented a trend to earlier maturation.
- The 1997 study indicates that stage 2 of breast and pubic hair development is being archived 1 year earlier in Caucasian females and 2 years earlier in African-American females than previous studies have shown.
- Concerns that girls with moderately precocious puberty will be significantly short adults are overstated; most have adult height within the normal range.
- Therapy with gonadotropin-releasing hormone agonists has not been proven to have a substantial effect on adult height in most girls whose puberty starts between 6 and 8 years of age.
- New guidelines propose that girls with either breast development or pubic hair should be evaluated if this occurs before age 7 in Caucasian females and before age 6 in African-American females. No changes in the current guidelines for evaluating males (signs of puberty at younger than 9 years) can be made at this time.<sup>11</sup>

Studies from the US show that the age of thelarche is falling more rapidly than the age of menarche. In addition, breast development is occurring, on average, 1-2 years earlier compared to 40 years ago. There is also a difference of thelarche being age 10 for Caucasian females, and age 9 for black females.<sup>12</sup> The age of menarche is also falling, with one study showing that the age of menarche has decreased by 9.5 months in black females and 2 months among Caucasian

females from 1973 to 1994.<sup>12</sup> Menarche is not a reliable marker for pubertal onset, as it is loosely correlated with the timing of pubarche and thelarche, although evidence shows that the onset of puberty with age of menarche appears to have decreased over the last few decades.<sup>12</sup> The decoupling of puberty's onset from menarche has been suggested to be due to environmental signals influencing thelarche and menarche in different ways.<sup>13</sup>

## Theories behind new pubertal trends

There are a numerous theories as to what has led to this increase in incidence of precocious puberty. These range from environmental causes,<sup>14,15,16,17,18,19,20</sup> prematurity and low birth weight,<sup>21,22,23,24</sup> obesity and BMI,<sup>19,20,25,26,27,28</sup> formula feeding<sup>29,30</sup> and poor family relationships in particular between father and daughter<sup>31,32,33,34</sup> just to name a few. To explore all the possible etiologies of precocious puberty is extensive, and beyond the objective of this paper.

Causes of precocious puberty are often due to early activation of the gonadotropic axis with pulsatile secretion of hypothalamic gonadotropin releasing hormone (GnRH), this then leads to an increase in luteinizing hormone (LH) and follicle stimulating hormone (FSH) secretion. This is effectively what occurs in what is termed Central Precocious Puberty (CPP).

Other forms of precocious puberty have been found to be due to autonomous production of sex steroids by the gonads or adrenals; from pharmacological or environmental exposure to sex steroids, or HCG production by tumors.<sup>35</sup> There are two classifications within precocious puberty being Central Precocious Puberty (CPP), and Pseudoprecocious or Peripheral Precocious Puberty. Pseudoprecocious Puberty is much less common, and refers to conditions in which increased production of sex-steroids is gonadotropin-independent.<sup>36</sup> Other causes include exogenous sex steroids or gonadotrophins, chronic primary hypothyroidism, ovarian tumours, benign ovarian cysts, feminising adrenal tumours, virilising adrenal tumors, McCune Albright syndrome to name a few.<sup>35</sup>

There is a fine line between what is considered within normal limits, on the outer edge of normal limits, and what may be an underlying pathology that may fit within the normal criteria. There is the opinion that if the newer guidelines are employed, then an under-diagnosis of endocrine conditions may be the result.<sup>37</sup> Most girls (95%) have idiopathic precocious puberty. Boys (>50%) are likely to have an underlying pathology resulting in precocious puberty.<sup>4</sup> According to one study, in which 1,570 patients

over a 5 year period at an outpatient endocrinology clinic; data was obtained on 105 (47.1%) of 223 patients found to have signs consistent with True/Central Precocious Puberty (CPP). Of these patients, 12.3% had other endocrine conditions including congenital adrenal hyperplasia, McCune Albright Syndrome, growth hormone deficiency, pituitary adenoma just to name a few.<sup>37</sup> In addition, a total of 35.2% of girls with CPP demonstrated bone ages >3SD above the mean; which often results in reduced growth potential. The researchers from this study suggest that based on this evidence that girls between the ages of 6-8 years showing the signs of puberty not be considered normal or benign. That accepting these new recommendations may actually result in failure to identify more serious underlying conditions that may respond to interventions.<sup>37</sup> Of course, on the opposing side of the argument is that if the age of puberty is declining based on secular trends, then these children may be exposed to extensive testing and investigations that are not required based on a variation of normal.

## Methods

An open literature review was conducted, using scientific journal databases Pubmed, Science Direct, Medline, Proquest, and Medscape. Search terms included 'adolescence', 'adolescent ages', 'puberty', 'precocious puberty', 'tween', 'childhood', 'childhood orthopedic conditions', adolescent orthopedic conditions. A general internet search was also conducted, using the above terms.

## Discussion

### *Precocious Puberty*

When a child is presented to the practitioner by a parent or caregiver with a concern over pubertal development, the practitioner must undertake a history and examination of the child to determine whether the child is presenting with pubertal onset within normal limits, or if there is the suspicion of precocious puberty. Furthermore, if it appears to be precocious puberty, whether it is indeed a Central Precocious Puberty (CPP) or Peripheral Precocious Puberty/Pseudoprecocious Puberty. To assist with assessment, Nields (2007) devised a list of questions for pediatricians to understand contributing factors. There are three overall components to address in the history — Past Medical History, Review of Systems (ROS) and Family History (*Table 1*). Physical examination recommendations for precocious puberty are also included as part of comprehensive analysis (*Table 2*).

It is vitally important when considering a potential diagnosis of this presentation to exclude CNS and gonadal

<b>A Past Medical History</b>	
i.	Pregnancy and birth complications, gestational age, neonatal course
ii.	Growth velocity and pattern
iii.	Childhood illnesses (CNS insults or infections)
iv.	Medications
v.	Radiation exposure
vi.	Exposure to potential hormone containing products (foods, cosmetics etc)
<b>B Review of Systems</b>	
i.	Pubertal changes (breast growth, pubic hair growth, acne, body odor, vaginal bleeding, hirsutism)
ii.	Age of pubertal changes
iii.	Rate of progression of pubertal changes
iv.	Neurological abnormalities (headaches, seizure, focal deficits, changes in emotional states, loss of temporal vision, polyuria, polydypsia, galactorrhea)
<b>C Family History</b>	
i.	Parental Height
ii.	Parental pubertal milestones <sup>38</sup>

**Table 1. Recommended history questions for precocious puberty.**

neoplasms.<sup>38</sup> Frequently ordered are imaging studies of the brain by MRI or CT.<sup>36</sup> Females should be referred for abdominoplevic ultrasound<sup>39</sup> as well as laboratory investigation of gonadotropin (mainly LH) response to GnRH.<sup>38</sup>

### Implications for chiropractors

As one might appreciate, the line of investigation can be quite extensive and appreciably expensive when looking for potentials as to early pubertal onset. There is a degree of concern on behalf of parents and caregivers as to the invasiveness of such procedures. There is also concern that due to such secular trends, practitioners may be over-investigating many cases where a new norm is emerging. Conversely, practitioners may potentially miss serious underlying disorders, if not caught in their early stages, which can potentially lead to very differing prognosis and outcomes.

<b>D Recommended examination procedures for precocious puberty</b>	
i.	Vitals be recorded such as height, weight, BMI all plotted and blood pressure recorded
ii.	Several previous growth measurements plotted to determine height velocity
iii.	Obtain parental heights so as to determine child's predicted height
iv.	Complete neurological assessment
v.	Dermatological assessment looking for discolorations, such as café au lait spots and axillary freckling of neurofibromatosis; as well as acne and acanthosis nigrans
vi.	Tanner method assessment for pubertal changes
vii.	Abdominal examination for any masses or enlargements
viii.	Thyroid examination for any abnormalities or enlargement
ix.	Testicular examination for any masses. <sup>38</sup>

**Table 2. Recommended physical examination for precocious puberty.**

Treatment itself for precocious puberty, is not within the scope of practice of the chiropractic physician. The outcomes, however, may be what present to the chiropractor based on what is known in terms of rapid skeletal growth. When practitioners consider the common orthopaedic conditions that may present to an allied health professional, these include, but are not limited to scoliosis, avascular necrosis (AVN), growth plate disorders, spondylolisthesis, which many have suggested to have marked changes during periods of hormonal changes during pubertal development. The potential list for such disorders are extensive, but what may be referenced in a textbook for age ranges for certain disorders may also need to be reconsidered due to these secular changes as well as emergence of precocious puberty.

What is also worthy of discussion is the other potential side effect of precocious puberty which may result in a chiropractic consultation. As an example, one may observe postural imbalances that may emerge in a young girl, embarrassed by her premature thelarche who is doing her best to conceal her developing chest with an increased thoracic kyphosis as compensation. There is also the threat



of stress, bullying and embarrassment that may result from premature development that may present with musculoskeletal complaints and compensations.

There are a few long term effects of precocious puberty worth noting. First, is the potential of compromised adult height due to premature closure of growth plates. Second, is a more serious long term effect being that females may be at greater risk of breast cancer due to increased exposure to estrogens, as well as the early puberty expanding intervals between first menses and pregnancy. This increased window is thought to increase vulnerability to the pathogenesis of breast cancer.<sup>40</sup> As well, long exposure to estrogen has also been seen as a risk factor for breast cancer in early breast development; where there is a long period between breast budding and initial ovulation.<sup>41</sup> Hence, the long term consequences may also be of concern to the health practitioner, including chiropractors. One paper in particular has investigated links between early menarche, and persistent pelvic pain and pelvic joint instability (PP-PJI) following parturition. Their study revealed that the women differed from the controls by a significantly lower age at menarche.<sup>42</sup>

### **What may be required for management and referral**

Chiropractors should be aware of the potential impact precocious puberty can have on onset and diagnosis of orthopedic conditions typically seen in the adolescent population. Practitioners could risk missing or discounting altogether clinical signs and symptoms if the patient is traditionally viewed as being 'too young' for a given diagnostic range. References give average range of onset for most disorders, but may not account for the emerging trend of earlier onset of puberty and accelerated skeletal growth. This is certainly an area where further research must be done. Numerous adolescent conditions present clinically at or around the time of the pubescent growth spurt. Those presenting more commonly to chiropractic offices include, but are not limited to, Scheurmann's Disease (Adolescent Kyphosis), Isthmic Spondylolisthesis, Adolescent Idiopathic Scoliosis, Legg-Calve Perthes Disease, Slipped Femoral Capital Epiphysis, and Osteochondritis Dissecans.

### **Adolescent orthopedic conditions**

Scheurmann's Disease typically affects adolescents aged 13-17 years. It is associated with vertebral endplate microfractures suffered during the adolescent growth spurt. This in turn affects growth, and results in anterior wedging through the thoraco-lumbar spine, and kyphotic postural distortion.<sup>43,44</sup>

Isthmic Spondylolisthesis involves a slippage of vertebra (frequently L4, L5) with concurrent pars defect (spondylolysis).<sup>43</sup> The onset of spondylolisthesis has been related to the adolescent growth spurt.<sup>45,46,47</sup> Seitsalo et al. (1991) also found through radiological studies, where onset corresponded to 'the growth spurt in early puberty there was a tendency to progress'.<sup>48</sup>

Adolescent Idiopathic Scoliosis is seen more commonly in females aged 10-25 years.<sup>43</sup> It involves curvature of the spine laterally, especially in the thoracic region. Onset occurs at, or prior to puberty.<sup>48,49</sup> Dimeglio et al. (2011) in a review of the literature, found that all 30 degree [scoliotic] curves presenting at the very beginning of puberty required surgery.<sup>49</sup>

Legg-Calve Perthes' Disease (LCP) is seen more frequently in males aged 3-12 years. It features an avascular necrosis of the femoral capital epiphysis prior closure of the growth plate<sup>43</sup> and leads to premature osteoarthritis. Although cases before age 2 are increasingly more common, Maus et al. (2008) reported a confirmed case of LCP in a 13-month-old.<sup>50</sup>

Slipped Femoral Capital Epiphysis occurs typically in males age 10-15 years during a period of rapid adolescent growth. It is seen as a slippage of the femoral neck about the femoral head, best viewed on frog-leg x-ray.<sup>43</sup> In a review of the literature, Brady and Price (2010) suggest that early or late onset may be secondary to endocrine factors, especially related to thyroid hormones.<sup>51</sup> A case series by Azzopardi et al. (2010) discusses 10 patients ages 5-10 years with SFCE. Although he suggests weight to be the major factor, one must acknowledge the potential for early onset as rates of both childhood obesity and younger onset of puberty increase.<sup>52</sup>

Osteochondritis Dissecans a disorder of adolescence features ischemic necrosis of subchondral bone, most commonly at the femoral condyle or capitellum. The cause is relatively unknown, although repetitive trauma during the adolescent years (age 10-20 years) are common factors.<sup>43,53</sup>

Practitioners should be cautious of disregarding clinical signs and symptoms of hormone-related orthopedic conditions, such as those mentioned, that may present in an evolving pediatric population. Long accepted age ranges for typical onset of adolescent orthopedic conditions have not yet accounted for the emerging trends of early adolescence, and there is potential for clinical signs to emerge earlier in life. Research is still being done into the effects

of such trends, however clinicians must have a high index of suspicion where history and/or examination lend itself to a particular diagnosis.

The conditions mentioned above may be seen in the normal pediatric population, however practitioners must also be aware of other pathological conditions seen in association with precocious puberty, such as McCune-Albright Syndrome (MAS). McCune-Albright syndrome has a tendency to produce polyostotic fibrous dysplasia where healthy bone is replaced by weaker, fibrous tissue. It presents on average between the ages of 8 and 11 years. Such a process can be seen on plain film radiography, and would present a contraindication to chiropractic adjustment.<sup>43</sup> Aycan et al. (2011) detail a case of MAS in a 5 year old girl with precocious puberty and multiple fractures.<sup>54</sup> Gucev et al. (2010) cite an MAS case in a 3-year-old girl with precocious puberty and fibrous dysplasia.<sup>55</sup>

## Conclusion

The purpose of this paper is to illustrate to the chiropractic clinician that many aspects must be considered when a child is presents either purely for investigation for early pubertal onset, or other conditions that may be a result of the changes associated with puberty. While investigation of either possibility may be within the scope of the practitioner, they should also call upon the expertise of other health care specialists, especially if the adolescent could possibly have an underlying condition contributing to an earlier pubertal onset. Part of the history and investigation should include a detailed neurological investigation and examination, based upon the possibility of a central nervous system disorder. In addition, when a child presents with a condition likely to occur during an adolescent period, then certain conditions should not be ruled out based solely on age.

## References

1. Santrock J. Puberty, Health and Biological Foundation. 2007. Website Accessed 21st November 2011. <http://highered.mcgrawhill.com/sites/dl/free/0073382612/569417/Chapter2.pdf>
2. Nields L, Nedim C, Kamat D. A Practical approach to precocious puberty. *Clin Pediatr* 2007; 46: 299.
3. Precocious Puberty (Early Puberty). December 2009. Website accessed 21st November 2011. [www.med.umich.edu/1libr/yourchild/puberty.htm](http://www.med.umich.edu/1libr/yourchild/puberty.htm)
4. Klein K. Precocious puberty: Who has it? who should be treated? *J Clin Endocrinol Metab* 1999; 84(2): 411-414.
5. Kaplowitz P. Precocious Puberty : Update on secular trends, definitions, diagnosis and treatment. *Adv. Pediatr* 2004; 51:37-62.
6. Tween. 2009. Website accessed 21st November 2011. <http://www.thefreedictionary.com/tween>
7. Tween. 2009. Website accessed 21st November 2011. <http://dictionary.reference.com/browse/tween>
8. Steingraber S. The falling age of puberty in U.S. girls: what we know, what we need to know. 2007. Website accessed 21st November 2011.
9. Styne D. Puberty and its disorders in boys. *Endocrinol Metab Clin North Am* 1991 Mar; 20(1): 43-69.
10. Hermann-Giddens M, Lora E, Wasserman R, Bourdony C, Bhapkar M, Koch G, Hasemeier C. Secondary sexual characteristics and menses in young girls seen in office practice: a study from the pediatric research office settings network. *Pediatrics* 1997; 99: 505-512.
11. Kaplowitz P; Oberfield S. Reexamination of the age limit for defining when puberty is precocious in girls in the United States: Implications or evaluation and treatment. *Pediatrics* 1999; 104(4): 936-941.
12. Steingraber S. The falling age of puberty in U.S. girls: what we know, what we need to know. 2007. Website accessed 21st November 2011.
13. Kaplowitz P. Pubertal development in girls: Secular trends. *Curr Opin Obstet Gynecol* 2006; 18: 487-91.
14. Colon I, Caro D, Bourdony C, Rosario O. Identification of phthalate esters in the serum of young puerto rican girls with premature breast development. *Environ Health Perspectives* 2000; 108(9) .
15. Krstevska-Konstantinova M, Charlier C, Crean M, Du Caju M, Heinrichs C, de Beaufort C, Bourguignon J. Sexual precocity after immigration from developing countries to belgium: Evidence of previous exposure to organochloride pesticides. *Hum Reprod* 2000; 16(5): 1020-26.
16. Michels Blanck H, Marcus M, Tolbert P, Rubin C, Henmderson A, Stover Hertzberg V, Zhang R, Cameron L. Age at menarche and tanner stage in girls exposed in utero and postnatally to polybrominated biphenyl. *Epidemiol* 2000; 11(6): 641-647.
17. Pasquino A, Balducci R, Manca Bitti M, Spadoni G, Boscherini B. Transient pseudo-precocious puberty by probable oestrogen intake in 3 girls. *Arch Dis Child* 1982; 57(12): 954-956.
18. Aksglaede L, Juul A, Leffers H, Skakkebaek N, Andersson A. The sensitivity of the child to sex steroids: possible impact of exogenous estrogens. *Hum Reprod Update* 2006 12(4): 341-349.
19. Walvoord E. The timing of puberty: Is it changing? Does it matter? *J Adolesc Health* 2010. 47(5): 433-9
20. Jorma T, Anders J. Trends in puberty timing in humans and environmental modifiers. *Mol Cell Endocrinol* 2010; 324(1-2): 39-44.
21. Ibanez L, Jimenez R, de Zegher F. Early puberty-menarche after precocious pubarche: Relation to prenatal growth. *Pediatrics* 2006; 117: 117-21.
22. van Weissenbruch M, Engelbregt M, Veening M, Delemarre-van de Waal H. Fetal nutrition and timing of puberty. *Endocr Dev* 2005; 8:15-33.
23. Hernandez M, Mericq V. Pubertal development in girls born small for gestational age. *Pediatr Endocr Met* 2008; 21: 201-208.
24. Neville K, Walker J. Precocious pubarche is associated with SGA, prematurity, weight gain and obesity. *Arch Dis Child* 2005; 90:258-261.
25. Lee J, Appugliese D, Kaciroti N, Corwyn R, Bradley R, Lumeng

- J. Weight status in young girls and the onset of puberty. *Pediatrics* 2007; 119(3): 624-630.
26. Kaplowitz P, Slora E, Wasserman R, Pedlow S, Herman-Giddens M. Earlier onset of puberty in girls: relation to increased body mass index and race. *Pediatrics* 2001; 108(2): 347-353.
27. Kaplowitz P. Link between body fat and timing of puberty. *Pediatrics* 2008; 121(Suppl 3): 208-17.
28. Ahmed M, Ong K, Dunger B. Childhood obesity and the timing of puberty. *Trends Endocrinol Metabol* 2009; 20(5): 237-242.
29. Novotny R, Daida Y, Grove J, Acharya S, Vogt T. Formula feeding in infancy is associated with adolescent body fat and earlier menarche. *Cell Mol Biol* 2003; 49: 1289-93.
30. Chen A, Rogan W. Isoflavones in soy infant formula: A review of evidence for endocrine and other activity in infants. *Annu Rev Nutr* 2004; 24: 33-54.
31. Moffit T, Caspi A, Belsky J, Silva P. Childhood experiences and the onset of menarche: A test of a sociobiological model. *Child Dev* 1992; 63: 47-58.
32. Ellis B, McFadyen-Ketchum S, Dodge K, Pettit G, Bates J. Quality of early family relationships and individual differences in the timing of pubertal maturation in girls: A longitudinal test of an evolutionary model. *J Pers Soc Psychol* 1999; 77: 387-401.
33. Bogaert A. Age of puberty and father absence in a national probability sample. *J Adolesc* 2005; 28: 541-46.
34. Tither J, Ellis B. Impact of fathers on daughter's age of menarche: A genetically and environmentally controlled sibling study. *Dev Psychol* 2008; 44(5): 1409-20.
35. Moore P. Practical management of precocious and delayed puberty in girls. *Obstetrics and Gynecology* 2006; 8(3).
36. Kaplowitz, P. Precocious Puberty. 2010. Website accessed 21st November 2011. <http://emedicine.medscape.com/article/924002/overview>
37. Midyett L, Moore W, Jacobson J. Are pubertal changes in girls before age 8 benign? *Pediatrics* 2003; 111(1).
38. Carel J, Lahlou N, Roger M, Chaussain J. Precocious puberty and statural growth. *Hum Reprod Update* 2004; 10(2): 135-147.
39. Moore P. Practical management of precocious and delayed puberty in girls. *Obstet Gynecol* 2006; 8(3)
40. Rosner B, Colditz G, Willett W. Reproductive risk factors in a prospective study of breast cancer: The nurses' health study. *Am J Epidemiol* 1994; 139: 819-35.
41. Okobia M, Bunker C. Epidemiological risk factors for breast cancer — A review. *NJCP* 2005; 9: 35-42.
42. Saugstad F. Is persistent pelvic pain and pelvic joint instability associated with early menarche and with oral contraceptives? *Eur J Obstet Gynaecol Reprod Biol* 1991; 41(3): 203-206.
43. Yochum Y, Rowe L. Essentials of Skeletal Radiology. 2nd Ed. Lippincott Williams & Wilkins. U.S.A. 1996.
44. Lowe T, Line B. Evidence Based Medicine: Analysis of Scheuermann kyphosis. *Spine* 2007 Sep; 32(19): 115-119 .
45. Hersinger R. Spondylolysis and spondylolisthesis in children. *Instr Course Lect* 1983; 32: 132-51.
46. Jalanko T, Helenius I, Remes V, Lamberg T, Tervahartiala P, Yrjonen T, Poussa M, Schlenszka D. Operative treatment of isthmic spondylolisthesis in children: a long-term retrospective comparative study with matched cohorts. *Eu Spine J* 2011 May; 20(5): 766-775.
47. Schlenszka D. Spondylolisthesis in childhood and adolescence. *Orthopade* 1997; Sep; 26(9): 760-8.
48. Dimeglio A, Canavese F, Charles Y. Growth and adolescent idiopathic scoliosis: when and how much? *J Pediatr Orthop* 2011 Jan-Feb; 31(1 Suppl): 28-36.
49. Goldberg C, Dowling F, Fogarty E. Adolescent idiopathic scoliosis — early menarche, normal growth. *Spine* 1993 Apr; 18(5): 529-35.
50. Maus U, Andereya S, Ihme N, Gravius S, Niedhart C, Ohnsorge J, Niethard F. Perthes' or Perthes' resembling disease in a 13-month-old boy. *J Pediatr Orthop B*: 2008 May; 17(3): 120-124.
51. Brady R, Price A. Delayed-onset slipped femoral epiphysis: case report of association with pituitary tumor. *Am J Orthop* 2010 Mar; 39(3): 137-40.
52. Azzopardi T, Sharma S, Bennet G. Slipped capital femoral epiphysis in children aged less than 10 years. *J Pediatr Orthop B*. 2010 Jan; 19(1): 13-8.
53. Benedict S, Oron A, Beer Y, Agar G. Osteochondritis dissecans of the knee. *Harefuah* 2008 Jul; 147(7): 618-23, 661.
54. Aycan Z, Onder A, Cetinkaya S. Eight-Year Follow-up of a Girl with McCune-Albright Syndrome. *J Clin Res Pediatr Endocrinol* 2011 Mar; 3(1): 40-2. Epub 2011 Feb 23.
55. Gucev Z, Tasic V, Jancevska A, Krstevsk-Konstantinova M, Pop-Jordanova N. McCune-Albright syndrome (MAS): early and extensive bone fibrous dysplasia involvement and "mistaken identity" oophorectomy. *J Pediatr Endocrinol Metab* 2010 Aug; 23(8): 837-42.





# An Investigation of Musculoskeletal Dysfunctions in Infants Including a Case Series of KISS Diagnosed Children

Josefa Langkau and Joyce Miller BS, DC, DABCO, FCC (UK), FEAC, FACO(US)

## ABSTRACT

**Objective:** The purpose of this study was to describe etiology, presentation and treatment of musculoskeletal issues in early infancy by integrating a case series of infants diagnosed with kinematic imbalance due to suboccipital sprain (KISS) and treated in a teaching clinic in the United Kingdom with a critical review of the concept of KISS. The concept has been developed by Heiner Biedermann and medical doctors in Germany and contributed significantly to the development of manual therapy in children in that country.

**Methods:** A literature review was conducted. The search was focused on German studies about KISS syndrome and English studies about musculoskeletal issues in infants. Search strategy: ZDB, ZB MED and PubMed and hand search in German libraries. The data were collected by survey via a data collection system and files in the Anglo European College of Chiropractic (AECC) teaching clinic.

**Results:** The primary differences between the diagnosis and treatment recommended by Biedermann and that in the AECC clinic are 1) the recommended use of x-ray prior to treatment by Biedermann and 2) recommended force used in treatment (4 N at AECC versus 70 N with Biedermann).

**Conclusion:** Musculoskeletal issues caused by birth and intrauterine posture are commonly observable and early treatment is often recommended; however, the grounding in evidence is not yet known. What this study adds to the literature is that:

- Radiologic evaluation of every child cannot be justified without any red flags due to known radiation hazards.
- Different treatments involve very different forces. Future studies about effectiveness and safety should focus on specific treatment style and force.
- There is no genetic component to develop KISS syndrome and the predisposition of male sex is more likely related to a bigger than average size at birth.

## Introduction

Musculoskeletal dysfunctions in the infant including torticollis, infantile scoliosis and facial asymmetry have been noted by various authors in the past two decades.<sup>1-7</sup> Facial asymmetries and head deformities in neonates are common and dysfunctional hip development has also been noted.<sup>4</sup>

The surgeon, Heiner Biederman, who contributed significantly to the development of manual therapy in children in Germany, also developed the concept of the kinematic imbalance due to suboccipital strain or “KISS-syndrome”. It suggests that functional abnormality in the atlanto-

occipital and atlanto-axial joints (for example, caused by birth trauma) might lead to a spectrum of symptoms and complaints in newborns.<sup>8</sup>

Infant positional preferences are common with this being present in 8%-12% of infants.<sup>9,10</sup> About 2.4% retained restricted range of motion and/or flattening of the skull at the age of 2 to 3 years. Other long term effects have been found. Sacher, for example, found that although dysfunction of the suboccipital joints might be asymptomatic during childhood, untreated functional abnormalities are thought to become persistent during skeletal maturity, leading to a fixed dysfunction causing symptoms in older children and adults.<sup>11</sup>

It is controversial as how to best react to asymmetric posture in infants. On the one hand it might be considered as being self-limiting.<sup>12</sup> On the other hand more recent studies imply the importance of treatment to avoid postural fixed dysfunctions causing long term problems in later childhood.<sup>8,11,13-15</sup>

**Josefa Langkau**

34 Morley Road, BH5 2JL, Bournemouth, United Kingdom

**Joyce Miller, BS, DC, DABCO, FCC (UK), FEAC, FACO(US)**

Associate Professor, Anglo-European College of Chiropractic, Bournemouth, United Kingdom

Corresponding author: [jmiller@aecc.ac.uk](mailto:jmiller@aecc.ac.uk)

Therefore it is important to investigate musculoskeletal diagnosing in infants with the help of early markers and examine whether the concept of early treatment might be justified. This paper aims to give a deeper understanding of musculoskeletal issues in children by putting KISS and KISS-induced Dyspraxia and Dyslexia ("KIDD"), Biedermanns' diagnostic concepts, into context within practice. Moreover, the presented case series on 23 symptomatic subjects adds to a critical evaluation of current treatment procedures for musculoskeletal problems in infants.

## Methods

The paper is a hybrid-type study, a narrative review combined with a case series. The literature review focused on German studies about KISS syndrome and English studies about musculoskeletal issues in infants. ZDB, ZB MED and PubMed were searched and the following search strategy was used: "Manipulation Spinal", "KISS + syndrome", "Kopfgelenk + Asymmetrie", "Suboccipital + strain" "Cervical-diencephal-statisches syndrome" "paediatric". Finally, the reference lists of relevant reviews were screened.

Additionally a wider search was done in libraries in Germany (Deutsche Nationalbibliothek Leipzig, Medizinische Bibliothek Charité Berlin) to gather older articles and journals which were not accessible in any internet database. The library was searched for relevant text book information.

For additional information and literature, telephone and email correspondence with Dr. Heiner Biedermann, specialist for KISS syndrome, have been used.

The data were collected by survey via a data collection system and files in the clinic to determine, describe and interpret the number of children presenting with KISS and identify the history, cause of presentation, physical findings and treatment given at the AECC teaching clinic. All consent forms had been signed and no individual child can be identified. All data are held completely confidential and data collection was approved by the ethics committee.

## Case series

A review of recent records showed that, between 2003 and 2010, 23 infants presenting to the chiropractic teaching clinic in Bournemouth, United Kingdom had been diagnosed with KISS syndrome. The

data collected included information suspected to be risk factors in *Table 1* and treatment specific data shown in *Table 2*.

The mean presenting age was 7-8 weeks and with a male:female ratio of 1.6:1.

13 of the 23 patients had a difficult and/or instrumental assisted labor. The children were all full term and the mean birth weight of 3,512 grams at the 50<sup>th</sup> centile in the growth chart.

Most common presenting complaints were restriction of rotation towards one side with or without difficulties breastfeeding. General restrictions and tenderness in the upper cervical segments and muscular tightness in the suboccipital region, as well as pelvic and SI joint fixations were noted. The most common differential diagnosis was irritable infant syndrome of musculoskeletal origin (IIS-MO) or biomechanical cervical dysfunction and treatment consisted mainly of touch and hold and occipital-sacral decompression technique.

## Discussion

KISS syndrome is thought to be caused by irritation of the cervical spine during birth,<sup>8</sup> which is a very demanding procedure for the infant and its spine.<sup>16</sup> Other authors found that asymmetry and restrictions are related to intra-uterine posture rather than birth trauma.<sup>4,7</sup> Children with a head preference to the right usually had an intrauterine posture to the right.<sup>17</sup> Nevertheless there is a correlation between craniofacial asymmetry and birth injuries.<sup>7</sup> It is most likely that both the intrauterine environment and birth injury contribute to the antalgic postures and asymmetries. The relationship between etiology mechanism and symptoms of KISS is shown in *Figure 1*.

The clinical picture of untreated KISS syndrome consists of four stages:<sup>20</sup>

- Up to 3 months: unspecific preliminary stage with symptoms of autonomic irritation and dysphoria (restlessness) e.g. crying babies and colic.
- 3-12 months: asymmetry during time scale of gaining head control until verticalization. The typical clinical presentation of KISS in this stage is summarized in *Table 3*.
- Verticalization until 4/5 years: symptom free, silent period.
- KISS-induced dysgnosia and dyspraxia ("KIDD syn-

**Table 1. Collected data from the chiropractic teaching clinic.**

	Gender	Method of Delivery	Gestation Age	Birth-weight in grams	Centile	Age at presentation	Weight at presentation	Centile	Height at presentation	Centile	Head circumference	Centile	Number of children birth order
1	female	Forceps	41 weeks	3600	75th	3 weeks	3300	9th	51	25th	35	25th	1
2	male	Home, vaginal, predipitous	40 weeks	3850	75th	7 days	3780	50th	48	2nd	34.5	9th	2
3	female	Normal vaginal	40 weeks	3203	50th	6.5 weeks	5520	50th-75th	58	75th	39.6	75th	3
4	male	Normal vaginal	40 weeks	3770	75th	3 weeks	4500	50th	54	25th-75th	39.2	91th	2
5	female	Delayed in birth canal, Ventouse	40 weeks	invalid data		6 weeks 6 days	invalid data		no data		40		1
6	male	Pre-eclampsia induced labor	37 weeks 6 days	3317	25th	9 weeks	no data		61	75th	40.4	50th	1
7	female	Umbilical cord around neck.	40 weeks	3538	50th	6 weeks	4092	25th-50th	54	25th	38.5	75th	1
8	female	Planned CS	38 weeks	2600	2nd	4 weeks	2640	below scale	48	0.4th	34	2nd	2 (2nd twin)
9	female	Vaginal	40 weeks	3125	25th	3 months 4 days	5760	50th	Could not be done		40	50th	1
10	male	Planned cesarean	38 weeks	3570	75th	7 weeks	5320	75th	56	50th	39	50th	2
11	male	Vaginal cord wrapped around neck	39 weeks	3320	25th	5 weeks	4910	75th	57	75th	38	50th	1
12	female	Ventouse Difficult birth	42 weeks	3500	50th	14 days	3760	50th	50	96	35	25th	3
13	male	Forceps, Streptococcal B infection.	40 weeks 6 days	4020	91st	6 days	4190	91st	54	91st	36.5	91st	1
14	male	Planned cesarean w/forceps	37 weeks	3300	50th	6 weeks	3960	9th	53	9th-25th	37	25th	3
15	male	Vaginal	41 weeks	4195	91st	33 weeks, 4 days	9800	98th	72.5	98th	49		2
16	male	Vaginal, difficult (13½ hours)	41 weeks	3750	75th	14.5 weeks	6580	50th	69.5	above scale	41.5	50th	1
17	male	Ventouse and forceps	41 weeks	4200	98th	9 weeks	6890	99.6th	60	91st	41	98th	1
18	male	Vaginal, prolonged 2nd stage, forceps	40 weeks 6 days	3625	50th	9 days	3720	50th	52	9th	34.5	2nd	1
19	female	Vaginal	40 weeks	3200	25-50th	11 weeks	5140	25-50th	57	9th-25th	38	9th	1
20	male	Vaginal	41 weeks 5 days	4110	91st	6 weeks	6300	89	62	99th	40	98th	1
21	male	Vaginal	38 weeks	2749	9th	7 weeks	no data		no data		40	75th	1
22	male	Vaginal, strong contractions, baby bruised	38 weeks	3062	25th	6 weeks	4890	50th	58	75th	37.5	25th	2
23	female	Normal vaginal, got stuck	38 weeks	2900	9th	6 weeks	4190	9th-	53	25th	37	25th	1
<b>MEAN</b>			<b>all full term</b>	<b>3512</b>	<b>52th</b>	<b>7-8 weeks</b>							<b>1st or 2nd child</b>

drome”): sensory-motor deficits leading to signs and symptoms of dysgnosia — relating to a form of intellectual impairment prohibiting learning; and dyspraxia — a form of cognitive dysfunctions that impair the ability to learn/use new motor-patterns.<sup>47</sup>

The data collection at the teaching clinic corroborates previous findings that males more commonly present with KISS syndrome.<sup>11</sup> Furthermore instrumental assisted delivery was common which is thought to be another risk factor contributing to the development of the KISS-syndrome.<sup>8</sup>

**Table 2. Collected data of the teaching clinic about presenting complaints, diagnosis and treatment.**

	Presenting complaint(s)	Physical findings	Differential diagnosis	Type of treatment given	Number of treatments recommended	Outcome
1	Check up	Bilateral fixation of C1-C2	KISS <b>Cervical dysfunction 2 secondary to traumatic birth</b>	Pediatric manipulation Soft tissue work	6 treatments (3/week for 2 weeks)	Normal movement noted
2	Difficulties breastfeeding Decreased left rotation restricted	Left rotation fixation Left C0-C1 and painful	<b>KISS (left)</b>	Soft tissue work  Touch and hold of upper Cx	2/week for 2-3 weeks	Free bilateral movement Resolved dysfunction Better sleep
3	Uncomfortable when lying down	Tight suboccipitals	<b>Mild KISS</b>	Pediatric style SMT Suboccipitals STW	8 treatments	Improved symptoms Slept better
4	Held head in rotation Discomfort spine	Moderately restless Cx restrictions	<b>KISS</b>	Pediatric SMT of Cx, pelvis Suboccipital stretch	4 treatments (2/week for 2 weeks)	Slight improvement Sleep improved
5	Refuses right Cx rotation Head needs to be turned to left when breastfeeding	DDH found Restriction C1-C2 on left Head in right lateral flexion and left rotation	KISS <b>Biomechanical Cx dysfunction</b> DDH	Pediatric SMT Touch and Hold Touch and Turn	4 treatments (2/week for 2 weeks)	Can move head more freely bilateral Symptoms resolved after 9 treatments
6	Not turning to left Misshapen head (R flattened) Colic	Asymmetry side to side Misplaced ears	<b>KISS</b> Colic	SMT, Soft tissue work to Cx	9 treatments	Can freely turn head colic resolved Parents notice difference in shape of head
7	Cannot turn head to right Reluctant to move shoulder	Sleeps with right hand on top of head	<b>Torticollis</b> KISS	Pediatric SMT Soft tissue work to shoulder	3 weeks	After 7 treatments 100% better, right and left equally No obvious restrictions
8	No weight gain Not opening mouth properly Not feeding well Right DDH Restless, difficult to settle	Slow development	IISMO Congenital torticollis Musculoskeletal irritability KISS	Treatment at C0-C4 Touch and hold	2 to 4 treatments	Rare irritated behavior good gain Mother feels less distressed Easier to console when crying Sleeps better 90% improvement after 4 weeks
9	Not looking to left Head in right lateral fixation Sleeping position with head to right	Irritable during examination Restriction C0-C5 on right, C1-2 left Hypertonicity T1-6 Hypertonicity traps	Torticollis, fibrosis, SCM KISS Positional plagiocephaly	TAH technique to upper and mid-Cx Massage upper trapezius	6 treatments 2/week for 3 weeks	After 3 treatments improved ROM Took 12 treatments to reach full ROM
10	Constantly unsettled Cries 11 hours/day; R flattened occiput too little sleep Head turned to right	Resisted left rotation of Cx Suboccipital fixations/pelvic	IISMO, colic, head Positional plagiocephaly	Touch and hold technique SMT	4 to 6 treatments 2/week for 2-3 weeks	Still occipital flattening, full CX ROM after 4 treatments
11	Head tilt	left sternocleidomastoid tight Cx + Tx restrictions Right SI restriction	Congenital torticollis IISMO <b>KISS</b>	Touch and hold technique Sacro-occipital decompression SMT	4 treatments (2/week for 2 weeks)	Generally 80% improvement
12	Not sleeping well Difficult to settle Irritable behavior Prefers left breast Arms held left	Tight left Cx, suboccipitals Restriction C0-C4 on left C1-2R, T4-7L; R SI joint left convex posture	Dysomnia Cx dysfunction IISMO <b>KISS</b>	Touch and hold to Cx Gentle massage	3 treatments 1/week for 3 weeks	Sleeping better Some restriction still felt after 3 treatments

Table 2 continued on next page

Table 2 (continued)

	Presenting complaint(s)	Physical findings	Differential diagnosis	Type of treatment given	Number of treatments recommended	Outcome
13	Check up after forceps delivery Favors lying on left side	Bruising; Fixations of right Cx (C0-C2, C5-C7) tight SI joints Cone shaped head Hypertonic muscles	Cx dysfunction due to birth trauma CMP1 <b>KISS</b>	Touch and hold to Cx and SI Myofascial release technique	4 to 6 treatments 2/week for 2-3 weeks	Muscles relaxed Dysfunction is resolved after 5 treatments
14	Unable to extend head Sucking too hard Head turned to left	Difficulty moving head to right Prefers left side Cx & SI restrictions Convex arching	<b>KISS</b> IISMO	Touch and hold technique Mastication muscle massage	5 treatments 2/week for 2 weeks; 1x for 1 week	Did not return
15	Abnormal head position fell off bed (1 meter) at 4 weeks of age	Right rotation of head Restrictions of C0-C2; also T9-12 SCM & trapezius tight	<b>KISS</b> Infantile torticollis Cx facet syndrome	Gentle massage Touch and hold technique	4 treatments 2/week for 2 weeks	Full Cx range of motion and no crying 100% better after 6 treatments KISS recovered
16	Difficulty turning head Favor left side	Restrictions of C0-C2 and left SI joint Symmetrical gluteal folds	Subacute, mild Cx & SI dysfunction <b>KISS</b>	Touch and hold technique to Cx & SI	4 treatments 2/week for 2 weeks	Improved sleep Feeding with head turned right after 4 treatments
17	Only looking to one side Increased crying Poor sleeping Abnormal head shape since birth	Cannot rotate to left Occipital flattening Asymmetric eye levels Tight SCM especially on right	<b>KISS</b> <b>Non-synostotic deformational plagiocephaly</b>	Touch and hold technique Massage to SCM Active counter positioning	6 treatments 2/week for 2 weeks then 1/week for 2 weeks	Moves head better after 3 treatments Resolved after 8 treatments No side preference any more
18	Check up after forceps delivery	Prefer right breast Restrictions of left Cx (C0- C2)	<b>KISS</b> IISMO	Touch and hold technique to C0-C4 Massages Touch and turn to right	6 treatments 2/week for 2 weeks then 1/week for 2 weeks	Resolved after 6 treatments Looks both ways, feeds off both breasts Right rotation slightly restricted
19	Constantly turning head to left Flattening of left occipital region	Tight left upper Cx Restrictions of C0-C4 on left TxL, Lx R; occipital flattening	Cx, Tx, Pelvic musculoskeletal dysfunction; CMT; plagiocephaly <b>KISS</b>	Touch and hold technique Myofascial release Occipital sacral decompression	6-8 treatments	Mother noticed increased range of motion after 3 treatments Better sleep
20	High pitched scream (fell on bottom) Seems uncomfortable in many positions	Occipital and Cx area tight on left Restrictions in mid-Tx SIJ restrictions; rigid abdomen	<b>KISS</b> Colic	Pediatric SMT Abdominal massage	4 treatments	After first treatment total relief from high pitched screams
21	Excessive crying Head in extension	Tender to motion palpitation of left upper Cx Left tight SCM	Infantile colic IISMO <b>KISS</b>	Touch and hold technique to Cx Suboccipitals & SCM massage	4 treatments within 2 weeks	Generally less crying Range of motion increased
22	Excessive crying Not looking to right	Painful restrictions at C0-C3 Painful Restrictions at T4-T6	<b>KISS</b> IISMO Upper Cx & pelvic imbalance	Mobilization of Cx, Tx, pelvis Occipital release	4 treatments 2/week for 2 weeks	Sleep better, less crying Right rotation increased Imbalance resolved after 6 treatments
23	Unsettled Always turns to left side Head tilted to right	Left neck tender and hypertonic Curls over right side Likes to keep left shoulder raised Right upper Cx tender & tight	<b>KISS</b> IISMO	Pediatric SMT to Tx and Cx STW to levator scapulae	3 treatments 1/week for 3 weeks	Still same position, still crying Slight improvement in tone Suboccipital region decreased tension

## Glossary of abbreviations

<b>Cx</b>	Cervical spine	<b>IISMO</b>	Irritable infant syndrome of musculoskeletal origin	<b>SI(J)</b>	Sacroiliac (joint)
<b>C0</b>	Occipital condyles	<b>KIDD</b>	KISS induced dysgnosia and dyspraxia	<b>TMJ</b>	Temporomandibular joint
<b>C1</b>	Atlas, first cervical vertebra	<b>KISS</b>	Kinematic imbalance due to suboccipital strain	<b>Tx</b>	Thoracic
<b>C2</b>	Axis, second cervical vertebra	<b>n</b>	Number of subjects	<b>&lt;</b>	below
<b>DDH</b>	Developmental dysplasia of the hip	<b>SCM</b>	Sternocleidomastoid	<b>&gt;</b>	above



**Table 3: Summary of presentation of KISS syndrome<sup>8</sup>**

KISS I			KISS II	
	Symptoms	Signs	Symptoms	Signs
MAJOR SIGNS & SYMPTOMS	Fixed unilateral head and trunk position	Torticollis	Fixed overextended posture especially when sleeping	Asymmetrical occipital flattening with KISS mark
	Facial and occipital symmetries	Asymmetric gluteal folds	Refuses to lie prone	C-scoliosis
	Impaired eye contact with parents	Asymmetric use of arms and legs	One-sided problems during breast feeding	Elevated shoulders
	Excessive crying especially when sleeping	Retarded development of the joints medial to the curve	Cold, sweaty hands and feet	Arms in “flying position”
			Impaired eye-contact with parents	Weak support when lying prone
			Excessive crying especially when sleeping	Weak musculature of mouth and neck stabilizers
				Colic
MINOR SIGNS & SYMPTOMS	Indistinguishable fever			
	Salivation and dysphagia			
	Cold, sweaty feet and hands			
	Delayed development of hip, usually unilateral			
	Malposition of feet, pes adductus			
	Hypersensitivity in cervical and shoulder area; do not like to get dressed or have clothes on			

The cases collected at the teaching clinic further supported the general literature<sup>24</sup> that manipulative therapy is very effective after 4-6 treatments for musculoskeletal issues in infants. When a fixation was detected, range of motion could almost always be improved. Although there was not always complete recovery, improvement was noted.

Comparing the common differential diagnosis to the symptomatic picture of KISS, a lot of similarities can be noted. A major difference is rather the perceived cause and consequent treatment plan. Whereas for IISMO it is suggested that the whole musculoskeletal system of the infant might lead to symptoms,<sup>6</sup> the whole spine will be in focus and specific imbalances will be treated. KISS on the other hand is thought to develop due to an imbalance in the cervico-occipital region; therefore the treatment plan involves only manipulation to the upper cervical spine.<sup>8</sup> Moreover, Biedermann suggests that one treatment might be enough to resolve symptoms in 80% of patients and recommends not treating too often

with leaving a pause of 2-3 weeks.<sup>8</sup>

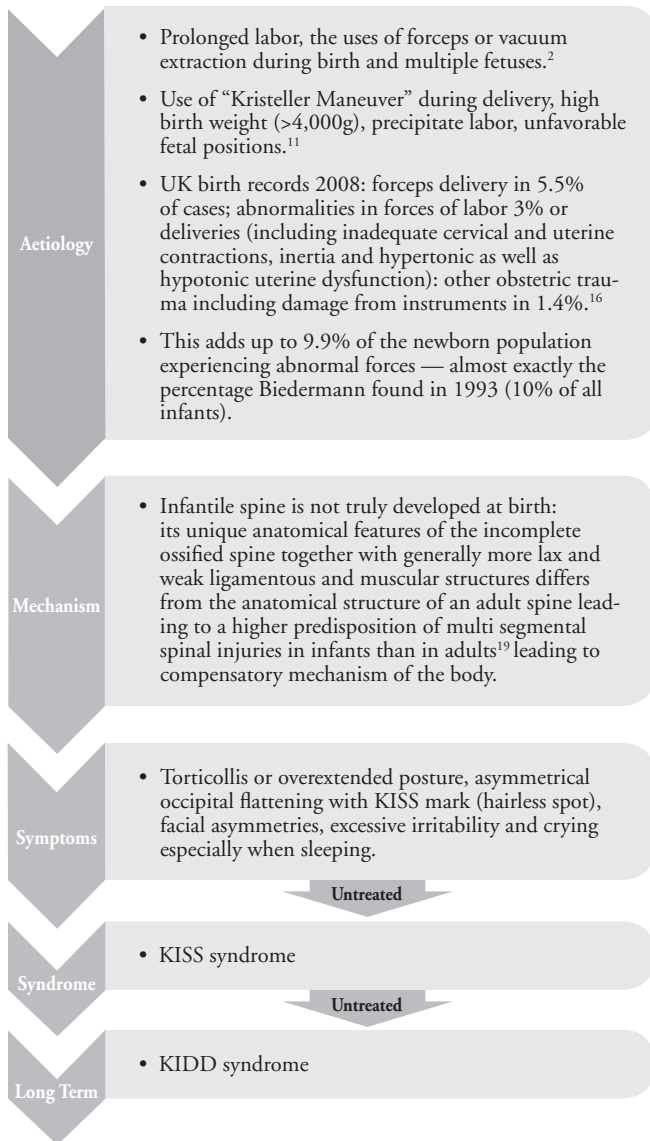
Most often touch and hold technique (TAH) is used as pediatric manipulative therapy. Up to 3 months of age, only light finger pressure should be used,<sup>21</sup> because the infantile cervical spine is not ossified<sup>22</sup> and therefore susceptible to compression forces. A gentle manipulation is not recommended until the child is one year of age.<sup>21</sup> Pressure should not exceed 85-141 grams<sup>21</sup> and the joint is not taken to its end range of motion.

Another technique used quite commonly was occipital-sacral decompression. With the infant supine a very gentle, light distraction is applied for 30 seconds, by contacting the occiput and sacral base, aimed to reduce tension and restrictions.<sup>23</sup>

This style of treating differs quite a lot from the treatment described by Biedermann. At the teaching clinic a very gentle approach to the whole spine is used to treat, and

**Figure 1.**

### Etiology mechanism and symptoms of KISS



that the force applied in those pediatric manipulations not exceed 4 Newton.<sup>21</sup> In contrast, Biedermann describes that to manipulate the fixation, a short impulse is given with the index finger towards the lateral mass of C1 or transverse process of C2, aiming to affect the cervical receptors. As the highest amount of proprioceptive muscle spindles is found in the upper cervical spine, it is thought to have the biggest effect on biomechanical motor function and balance.<sup>25</sup> Koch and Girnus<sup>26</sup> measured the force of an impulse for a pediatric manipulation done by Biedermann and Koch to be 70 Newton.

This is one of the major differences between treatments — the treatment at the teaching clinic involves

one twentieth of the force compared to the force applied by Biedermann. Since the major issue of manipulative therapy is safety, especially for pediatric patients who have delicate anatomy, this difference might be important. However, hardly any paper actually refers to a specific style of treatment and there is no report of adverse events associated with the Biedermann methods versus the low force techniques performed in the chiropractic clinic setting.

In future studies about adverse effects, focus should be put on the force of treatment as well as the type of treatment used to give a more detailed picture.

A genetic component has been suggested to the predisposition to developing KISS,<sup>8</sup> since males were affected more frequently than females. However, when comparing the growth charts of male and females, a difference in head circumference is noticeable. Whereas for girls a head circumference of 37 cm at birth is in the 99.6<sup>th</sup> centile, in boys the 99.6<sup>th</sup> centile is related to a head circumference of 39 cm.<sup>27</sup> It is further known that male infants have a more prominent occipital protuberance.<sup>28</sup> According to the WHO growth charts, male neonates are usually bigger as well. A bigger head circumference and size is a known predisposing factor for injuries,<sup>11,29,30</sup> leading to the conclusion that size is more likely to explain the ratio than an unknown genetic component.

In contrast to the diagnostic procedure in the teaching clinic where no child will be x-rayed, Biedermann states that an x-ray of the cervico-occipital region needs to be made before treating the patient to rule out any pathology and important anomalies. This diagnostic process is criticized by the German association for neuro-pediatrics because it adds an additional risk of radiation hazards.<sup>31</sup> Infants may be more susceptible to the effects of radiation.<sup>32</sup> Especially in newborns the cells are still developing; therefore they are rapidly dividing.<sup>33</sup> It is known that dividing cells are easily affected by radiation,<sup>32</sup> which might lead to genetic mutations. Even if the consequences of one-time radiation are not fully researched, various studies show a correlation between long-term radiation in childhood and the incidence of acute and chronic side effects including malignancy.<sup>34,35,36</sup>

It is always important to consider potential risks and benefits when deciding to x-ray a patient.<sup>34</sup> The prevalence of KISS-syndrome is thought to be relatively high; therefore long-term effects of radiation should be considered. The manipulating therapist should have a very good education

about contraindications of manipulation. A thorough history and examination for every patient might be enough to obtain suspicious findings or potential contraindications to treatment. Then an x-ray could be done to prove suspicion of a specific pathology instead of x-raying every infant presenting to the practice.

Therefore we suggest the following:

- There is no genetic component to developing KISS syndrome as stated by Biedermann — predisposition of male sex is rather caused by bigger average size at birth.
- Radiologic evaluation of every child cannot be justified without any red flags due to known radiation hazards.
- Future studies about effectiveness and safety should focus on specific treatment style and force.

### **Suspected long term effects of untreated KISS syndrome**

Musculoskeletal imbalances, such as KISS syndrome are functional problems of the cervical spine which is still plastic and changeable.<sup>37</sup> Therefore it can be resolved by early treatment, whereas untreated it might become a structural problem of the cervical spine.<sup>38-40</sup> Some authors state, based on case studies, that the symptomatic cases will resolve spontaneously<sup>12,41</sup> questioning if early therapy is effective and if it is needed.<sup>12</sup> However, children may become asymptomatic but still have reduced head range of motion with sensory-motor dysfunctions<sup>8,9,15,40,42,43</sup> which may lead to other functional problems.

Studies reveal that positional head deformities are still persistent in one third of the affected children after 2-3 years,<sup>9</sup> and early treatment and education<sup>7</sup> for infants might effectively reduce neck problems, and head preferences otherwise leading to cosmetically significant<sup>44</sup> long-term plagiocephaly.<sup>3,5,45</sup> The association can also be noted by the trends in clinician referral with suspicion of KISS. In 1999 the prevalence of children referred to Biedermann with suspicion of KISS was due to torticollis in 89.3%; in 2003 53% of children have been referred for torticollis but 67.6% for cranial asymmetry.<sup>46</sup>

It is suggested that in a dysfunctional upper cervical spine, tonic neck reflex receptors cannot transmit the information correctly, leading to impaired perception.<sup>47</sup> The cervical spine musculature has many more muscle spindles and proprioceptive receptors than the lower back musculature,<sup>48</sup> meaning that the upper cervical spine might be

important for smooth functioning of perception and motor control.<sup>49</sup> This thesis is supported by a study by Owens et al.<sup>50</sup> which evaluates the repositional accuracy of students with contracted, shortened muscles, concluding that cervical paraspinal musculature contraction influence the proprioceptive accuracy of the neck. Therefore dysfunction in the upper cervical spine may have an impact on the quality of the kinesthetic system, leading to impairment in sensation causing a dysfunction in development of fine motor skills.<sup>8</sup> This theory finds anecdotal evidence in studies from whiplash patients. The traumatic acceleration-deceleration injury of the neck and surrounding structures<sup>51</sup> was found to cause muscular imbalance and cervical spine dysfunction, leading to poorer motor control, especially reduced joint position sense.<sup>52,53</sup> Even if the mechanism of injury is different from birth, these studies provide evidence that injuries to the cervical spine might lead to dysfunctions that affect the sensory-motor system, especially proprioception. Moreover, a recent meta-analysis found an association between regulatory problems like crying, feeding problems and sleeping problems (that contribute to the symptomatology of KISS) and later behavioral problems.<sup>13</sup>

The symptoms of KISS are thought to progress and it is suspected that, because “form follows function,” long-term effects might develop from untreated KISS. Many sources in the literature recommended early treatment and case studies showed manipulative therapy to be effective in reducing early dysfunctions and therefore signs and symptoms of KISS and preventing long-time deformities.

However there is minimal evidence for observed behavioral changes and attention deficits as described. Even if sensation and proprioception might be altered by dysfunctional joints, it is questionable if this accounts for a variety of long term effects. More research is needed to give a clearer picture.

Other studies about infant torticollis, asymmetry and head deformities also conclude that early treatment is favorable to prevent long-term deformities.<sup>3,7</sup> Especially sufficient education<sup>4,5</sup> and adequate amount of “tummy time” is suggested to be favorable, because it stretches the tight musculature (especially SCM) and strengthens trunk stability.<sup>7</sup> Further physical therapy is recommended in infants with reduced neck range of motion.<sup>7</sup>

### **Limitations**

It might be concluded that, apart from the small number of patients and the subjectivity of reporting, chiropractic treatment for KISS syndrome at the teaching clinic



appears to be effective and safe (although this type of study cannot adequately determine either). The limitations of case series do not allow for statements of efficacy, but can merely show trends. Randomized controlled trials would be best to address effectiveness of treatments. Moreover a long-term follow up has not been made. Considering the suspected long-term effects, further studies should be done addressing these issues.

## Conclusion

In general, this paper was intended to give a better understanding about musculoskeletal issues in infants. By using many German research articles and combining it with cases from the teaching clinic, it gives a deeper insight and a better understanding of the concepts of KISS syndrome and its long-term effects.

## References

- Buchmann J. and Bülow B. Funktionelle Kopfgelenkstörungen bei Neugeborenen im Zusammenhang mit Lagerfunktionsverhalten und Tonusasymmetrie. *Man Med* 1983; 21:59-62.
- Biedermann H. Das KISS- Syndrom der Neugeborenen und Kleinkinder. *Man Med* 1993; 31:97-107.
- Capiter G, Dessauge D, Picot MC, Bigorre M, Gossard C, El Ammar J and Leboucq N. Classification and Pathogenic Models of Unintentional Postural Cranial Deformities in Infants: Plagiocephalies and Brachycephalies. *J Craniofac Surg* 2011; 22(1):33-41.
- Hamanishi C, and Tanaka S. Turned head-adducted hip-truncal curvature syndrome. *Arch dis child* 1994; 70:515- 9.
- Hutchinson K J, Hutchinson LAD, Thompson JM. and Mitchell E. Plagiocephaly and brachycephaly in the first two years of life: a prospective cohort study. *Pediatr* 2004;114:970-80.
- Miller JE. Cry Baby: A framework for Chiropractic care. *Clinical Chiropractic* 2007;10:139-46.
- Stellwagen L, Hubbard E, Chambers C and Lyons Jones K. Torticollis, facial asymmetries and plagiocephaly in normal newborns. *Arch dis child* 2008; 93:827-31.
- Biedermann H. Kiss-Kinder-Ursachen, (Spät-)Folgen und manualtherapeutische Behandlung frühkindlicher Asymmetrie. 3 Auflage, Stuttgart: Thieme; 2007.
- Boere-Boonekamp M and Van der Linden-Kuiper L. Positional Preference: Prevalence in Infants and Follow-Up After Two Years. *Pediatr* 2001; 107(2):339-43.
- Happle C, Wetzke M, Hermann EJ, Krauss JK, Hartmann H and Lücke T. Cases against "KISS": Ein diagnostischer Algorithmus des frühkindlichen Torticollis., Hannover: Medizinische Hochschule Hannover, Kinderheilkunde; 2009.
- Sacher R. Geburtstrauma und (Hals-)Wirbelsäule — Teil II: Peripartale Risikofaktoren für die Entstehung von frühkindlichen Kopfgelenkblockierungen — eigene Untersuchungen unter Berücksichtigung der ISG-Funktion. *Man Med* 2003; 41:15-21.
- Fernandez-Alvarez E. Transient movement disorders in children. *J Neurol* 1998; 245(1):1-5.
- Hemmi MH, Wolke D and Schneider S. Associations between problems with crying in sleeping and/or feeding in infancy and long term behavioral outcomes in childhood: a meta-analysis. *Arch dis child* 2011; 96:622-9.
- Ho BCS, Lee EH and Singh K. Epidemiology, Presentation and Management of Congenital Muscular Torticollis. *Singapore Med J* 1999; 40(11):675-9.
- Williams-Frey S. Management of atypical infant colic — a pain syndrome of infancy — and the emotional stress associated with it: Why treat a benign disorder? *Clinical chiropractic* 2011; 14(3):91-6.
- Moeckel E and Mitha N. Textbook of pediatric osteopathy. Philadelphia: Elsevier; 2008.
- Michel GF and Goodwin R. Intrauterine birth position predicts newborn supine head position preferences. *Infant behav dev* 1979; 2:29-38.
- The Health and Social Care Information Centre, 2009. Table 22: Complications recorded during the delivery episode, 2008-09.UK Available from <http://www.chiroandosteo.com> [Accessed 20.10.2010].
- The Cervical spine research society editorial committee. The cervical spine. Fourth Edition. Philadelphia: Lippincott Williams & Wilkins; 2005.
- Biedermann H. and Koch L. Zur Differentialdiagnose des KISS syndroms. *Man Med* 1996; 34:73-81.
- Miller JE. Pediatric Essentials for the Chiropractor. Bournemouth: AECC Manual; 2009.
- Fysh PN. *Chiropractic Care for the pediatric patient*. Arlington: International Chiropractors Association Council on Chiropractic Pediatrics; 2002.
- Browning M and Miller J. Comparison of the short-term effects of chiropractic spinal manipulation and occipito-sacral decompression in the treatment of infantile colic: A single blinded, randomized comparison trial. *Clinical Chiropractic* 2008; 11:122-9.
- Vallone SA, Miller J, Larsdotter A and Barham-Floreani J. Chiropractic approach to the management of children. *Chiropr Osteopat* 2010;18(16). Available from <http://www.chiroandosteo.com> [Accessed 20.10.2010].
- Marks V and Kemlein W. Symptomatik und Diagnostik des Tonusasymmetrie- Syndroms im Säuglingsalter. *Pädiatrische praxis* 2001; 60:243-53.
- Koch LE and Girnus U. Kraftmessung bei Anwendung der Impulstechnik in der Chirotherapie. *Man Med* 1998; 36:21-6.
- WHO Department of Health, RCPCH. UK- WHO Growth Charts: Early Years. Glasgow: WHO, Department of Health, RCPCH; 2009. Available from: <http://www.rcpch.ac.uk> [Accessed 14.December 2010].
- Steele DG and Bramblett CA. The anatomy and biology of the human skeleton. 8th edition. College Station: Texas A & M University Press;1988.
- Hughes C A, Harley EH, Milmo G, Bala R and Martorella A. Birth Trauma in the Head and Neck. *Arch otolaryngol head neck surg* 1999;125(2):193-9.
- Perlow JH, Wington T, Hart J, Strassner HT, Nageotte MP and

- Wolk BM. Birth trauma: A Five-Year Review of Incidence and Associated Perinatal Factors. *Obstet Gynecol Surv* 1997; 52(6): 339-40.
31. Karch D, Boltshauser E, Groß-Selbeck G, Pietz J and Schlack HG. Manualmedizinische Behandlung des KISS-Syndroms und Atlasterapie nach Arlen; Stellungnahme der Gesellschaft für Neuropädiatrie e.V. *Man Med* 2005; 43:100-5.
32. Folkers C and Olson M. Radiation and children: The ignored victims. Nuclear Information and Resource Service; 2004. Available from: <http://www.nirs.org> [Accessed 07. January 2011].
33. Siegelman CK, Rider EA. Life-Span Human Development. 6th edition. Belmont: Wadsworth Cenage Learning; 2009.
34. Boelling T, Schuck A, Rübe C, Hesselmann S, Pape H, Dieckmann K, Pöllinger B, Kortmann RD, Speiser-Held I, Meyer FM, Martini C, Asadpour B, Timmermann B, Beck JD, Langer T, Paulides M, Schmidt B and Willich N. Study protocol of the German "Registry for the Detection of Late Sequelae after Radiotherapy in Childhood and Adolescence" (RISK). *Radiat Oncol* 2008. Available from: <http://www.ro-journal.com> [Accessed 07. January 2011].
35. Danoff BF, Cowchock S, Marquette C, Mulgrew L and Kramer S. Assessment of the long-term effects of primary radiation. Therapy for brain tumors in children. *Cancer* 2006; 49(8):1580-6.
36. Oeffinger KC, Mertens AC, Sklar CA, Kawashima T, Hudson MM, Meadows AT, Friedman DL, Marina N, Hobbie W, Kadan-Lottick NS, Schwartz CL, Leisenring W and Robison LL. Chronic health conditions in Adult Survivors of Childhood Cancer. *N Engl J Med* 2006; 355:1572-82.
37. Akbar M, and Wiedenhöfer B. Korrektur der Adoleszentenkyphose. Was ist State of the Art? *Der Orthopäde* 2011; 40(8): 682-9.
38. Coenen W. Bewegungsstörungen im Säuglingsalter-Klinische Differenzierung zentraler und peripherer Ursachen. *Man Med.* 2011; 49(3):171-88.
39. Goebelt T. Effektivität Manueller Therapie bei der Behandlung von Kindern mit KISS-Syndrom-Vorstellung eines biomechanisch-funktionellen Behandlungsansatzes. Thesis, (B.Sc.). Fachhochschule Schloss Hohenfels; 2010.
40. Saedt E., Schamberger T. and van der Woude B., KISS in den Niederlanden-Aktueller Stand. *Manuelle Therapie* 2010; 14(1): 7-13. Original article: Saedt E, Schamberger T and van der Woude B., KISS in Nederland — The state of the art. *Tijdschrift voor Manuele Therapie (TMT)* 2008;1:30-6.
41. Basheer SN. Paroxysmal torticollis. *J Pediatr Neurol* 2010; 8:69-71.
42. Miller JE and Phillips HL. Long-Term Effects of Infant Colic: A Survey Comparison of Chiropractic Treatment and Nontreatment Groups. *J Manipulative Physiol Ther* 2009; 32(8):635-8.
43. Stuecker R. Die mit Plagiozephalus assoziierte Säuglingsasymmetrie. *Zeitung für Orthopädie und Unfallchirurgie* 2009; 147(4):503-12.
44. Hudgins RJ, Boydston WR, Reisner A and Brahma B. *Neuro-update*. Atlanta: Children's healthcare of Atlanta; 2008.
45. Sergueef N, Nelson KE and Glonek T. Palpatory diagnosis of plagiocephaly. *Complement Ther Clin Prac* 2006; 12(2):101-10.
46. Biedermann H. Manual therapy in children. London: Churchill Livingstone; 2004.
47. Sacher R. Handbuch KISS KIDDs-Entwicklungsauffälligkeiten im Säuglings-Kleinkindsalter und bei Vorschul-/Schulkindern-Ein manualmedizinischer Behandlungsansatz. Dortmund: Verlag modernes lernen; 2007.
48. Bein-Wirzbinski B, Scheunenmann R and Sepke C. Mögliche Zusammenhänge zwischen Kopfgelenkdysfunktionen und blickmotorischen Auffälligkeiten bei Grundschulkindern mit Schulschwierigkeiten. *Man Med* 2008; 46:307-15.
49. Boyd-Clark LC, Briggs CA, Galea MP. Muscle Spindle Distribution, Morphology and Density in Longus Colli and Multifidus Muscles of the Cervical Spine. *Spine* 2002; 27(7):694-701.
50. Owens EF, Henderson C, Gudavalli RM and Pickar JG. Head repositioning errors in normal student volunteers: a possible tool to assess the neck's neuromuscular system. *Chiropr Osteopat* 2006;14(5) Available from <http://www.chiroandosteo.com> [Accessed 10.11. 2010].
51. Foreman SM and Croft AC. Whiplash injuries — The cervical acceleration/deceleration syndrome. Third Edition, Philadelphia: Lippincott Williams & Wilkins; 2002.
52. Jull GA. Deep cervical neck flexor dysfunction in whiplash. *J musculoskelet pain* 2008; (1-2):143-154.
53. Sterling M, Jull G, Vicenzino B, Kenardy J and Darnell R. Development of motor system dysfunction following whiplash injury. *Pain* 2003;103(1):65-73.



# Recognition of Perinatal Stroke in a Chiropractic Practice: Case Report and Clinical Challenges Related to a Late Diagnosis

Christine Bourdeau, DC

## ABSTRACT

**Introduction:** In recent years, improvements in medical techniques and technology have enabled primary health care practitioners to diagnose perinatal strokes in infants far earlier than ever before. This new technology can also support chiropractors, especially those working with pediatric patients, in order to validate their diagnosis when they recognize these initial symptoms.

**Objective:** The aim of this paper is to raise awareness and assist doctors of chiropractic in recognizing the physical and behavioral signs of perinatal stroke as they present in a chiropractic office for assessment and treatment. The paper will relate the case of a 7-month-old infant who, after visiting a chiropractic office with apparent hemiparesis and delayed developmental milestones, was post-medically diagnosed as having suffered a presumed perinatal stroke.

**Discussion:** Early recognition of perinatal stroke is vital since late diagnosis can lead to a lifetime of debilitating neurological conditions as well as potential increased direct and indirect costs to society. For those who receive a late diagnosis, a chiropractor, as a member of a multidisciplinary team, can play a major role in rehabilitation by supporting the function of the nervous system, reducing muscle and joint rigidity and optimizing neuronal plasticity.

**Conclusion:** It would be prudent for chiropractors to receive more training in the detection of perinatal stroke. Early detection can be accomplished by way of a comprehensive questionnaire and focused physical examination. The early detection of possible perinatal stroke will permit a referral to the proper professional and rapid intervention which will increase the likelihood of a positive outcome. More studies need to be done to reach a better understanding of the pathophysiology of perinatal strokes. Clinical guidelines also need to be established that will improve the prognosis for pediatric patients.

**Key words:** perinatal stroke, infantile stroke, fetal stroke, presumed prenatal stroke, chiropractic, west syndrome, hemiparesis, cerebral palsy, delayed milestones, rehabilitation

## Introduction

Perinatal strokes are now estimated to occur in 1 in 4000-5000 newborn babies.<sup>1-4</sup> As a result of today's new imaging technologies, the rate of diagnosis of this condition is on the rise. Because symptoms may not appear until a baby is between the ages of 4 to 6 months, a chiropractor may be the first health care professional that parents seek out when they encounter difficulties while breastfeeding or become aware of a delay in reaching expected developmental milestones. Chiropractic is a health care profession that focuses on disorders of the musculoskeletal system and the nervous system, and the effects of these disorders on general health.

At a perinatal stroke workshop held in 2007, perinatal ischemic stroke was defined as a group of heterogeneous conditions where neither a focal disruption of cerebral

blood flow secondary to arterial ischemic stroke (AIS) or cerebral venous thrombosis (CVT) occurs nor embolization (hemorrhage) between 20 weeks of fetal life to the 28th post-natal day, and confirmed by neuroimaging or neuropathological studies.<sup>5-7</sup> If blood flow is interrupted for a period of time longer than a few seconds, the brain can be permanently damaged. Early recognition is important and contributes to an improved prognosis. 80% of all perinatal strokes are ischemic while the remainder are hemorrhagic or venous.<sup>8</sup>

As recommended by Raju et al. (2007), perinatal strokes can be classified more effectively by the timing of their detection rather than by the time of onset.<sup>5</sup> Therefore, we divide them into three categories; fetal stroke, neonatal stroke and presumed fetal or neonatal stroke. The last category involves obtaining evidence from an imaging study of a long-standing stroke without previous clinical symptoms. In these cases, though, suspicions were raised because of the higher prevalence of chronic neurological deficits and cerebral palsy.<sup>5,7,9</sup>

**Christine Bourdeau, DC**

*Private practice: Montreal, Quebec, Canada*

*Email: christine.bourdeau@videotron.ca*

The clinical presentation of a perinatal stroke depends on the age of the child at the time of diagnosis. In newborns that are diagnosed in the early stages, 25 to 40% have seizures.<sup>3</sup> This is the most common trigger for the provision of more detailed assessment. Most seizures are focal and infants may appear well between seizures. Other systemic signs, if present, are nonspecific and subtle and may include difficulty feeding, hypotonia, lethargy, or apnea. In neonatal strokes diagnosed retrospectively (also called presumed neonatal stroke), the presentation includes asymmetry of reach and grasp, hemiparesis, failure to reach developmental milestones, or post-neonatal seizures.<sup>3</sup>

Medical management consists of aggressively treating the symptoms, mostly seizures. In the presence of refractory hemispheric epilepsy, hemispherotomy and functional hemispherectomy could be indicated to reduce or eliminate seizures and promote neurological development<sup>10</sup> in the infant, and later, the child. To our knowledge, the current literature contains no studies or case reports on chiropractic management (CINAHL (EBSCO), Medline, Pubmed, Index to chiropractic literature). It is possible that chiropractors can play a major role in increasing brain plasticity thereby optimizing long term functionality as part of a multi-disciplinary team approach. Today's chiropractors need to remain current on the information pertaining to this condition in order to assess patients utilizing detailed case history, a thorough physical examination to clarify the diagnosis, recommend referrals, and be members of the rehabilitation team alongside other health care professionals.

For the purposes of this paper, childhood stroke will not be discussed; detailed information is provided elsewhere.<sup>1,8,11</sup>

## Case Presentation

A female infant was born at 38 weeks, 4 days gestation to a 37-year-old mother, gravida 4 para 4. The history of the pregnancy was unremarkable with the exception of some medication administered for nausea (Diclectin®) which was taken in the first trimester. Two ultrasounds were performed at 12 and 28 weeks respectively and were normal. The birth was a normal vaginal delivery with APGAR scores of 9-10 after 1 and 5 minutes. Total labor time was 6 hours with 45 minutes of pushing; the baby presented posteriorly and had to be assisted by manual extraction. No medication/sedation was administered during labor, no stimulation of labor or epidural anesthesia; no placental examination was performed. The mother was discharged from the hospital within 72 hours, without any apparent problems. Breastfeeding was difficult at first. When the baby initially

latched, the suckle was weak attributed to the sleepy state of the baby, but the mother persevered and was ultimately successful. In this case, the mother was experienced, knowledgeable and was a breastfeeding support mother in a lactation group. During her hospital stay, she was expressing milk and giving it to the infant with a spoon. In her first month of life, the baby also required an intervention for a posterior tongue tie which also contributed to difficulties with latch and transfer of milk.

In the first months, the mother reported some slight delays in the baby's attainment of expected developmental milestones. She noticed that her baby was not as alert as her other children were at the same age, but she was able to smile and interact with others. By comparison, eventually she noticed that some significant milestones were delayed, these included; head holding, an absence of ventral positioning and an asymmetry in the use of her upper extremities. She reported that a few weeks after birth, the baby was not using her right arm as much as the left one and that her hand was mostly held in a fist and maintained in flexion. At the age of six months, the baby was moving her arm at the elbow joint and her hand was able to open more frequently. During her last medical visit at 6½ months, the medical doctor expressed no concern about the infant's condition and the delayed milestones and suggested a follow up a month later. She demonstrated no ability to sit and was not comfortable lying in the prone position ("tummy time"). It is notable that the child was the family's 4th daughter and that the mother, based on her previous experiences, was aware that something was wrong.

The baby was brought to our office for a physical evaluation at 7 months. Observations showed reduced facial expressions with an asymmetry of the eye gaze, the right eye having a tendency to diverge at some point and a delay in the active cervical motion when following objects. She was able to smile although she was reluctant, not often making eye contact. The level of activity of the upper extremity was reduced and asymmetrical although she was using the upper extremity mostly at the elbow and within 60 degrees of shoulder flexion on the right side. The baby was uncomfortable in the ventral position and displayed a lack of extension at the occipital and cervicothoracic areas. She wasn't able to turn on either side and failed to attempt to do so even when stimulated. The infant could not sit up, with or without support, and she was unable to be pulled up by hand into a sitting position. She was able to bring objects close to her mouth with her left hand only.

The cranial evaluation showed normal fontanels. Some



cranial restrictions were noted in the following bones; parietal, frontal, temporal, occiput, and sphenoid. Light palpation of the cranials elicited a withdrawal reflex accompanied by crying and palpation of the upper cervical region as well. Tongue movement was within normal limits and sucking occurred during breastfeeding though the infant refused to do so when stimulated digitally.

The range of motion of the cervical spine was restricted in right rotation and in flexion/extension with tension at the suboccipital area. The occiput was slightly fixed in extension. The range of motion (ROM) of the right shoulder, clavicle and scapula were restricted and elicited a crying response from the baby. The pectoralis, SCM, scalene, subclavian, biceps, subscapularis, upper trapezius, and levator scapula muscles were all hypertonic on the right side; The ROM of the right hip was also reduced mostly in long axis traction and internal rotation but both legs were restricted and positioned in abduction and external rotation.

During the neurological examination, the Babinski reflex was present bilaterally but slightly reduced on the right side. The palmar grasp reflex, the Moro reflex and the ATNR (asymmetric tonic neck reflex) were reduced on the right side. Deep tendon reflexes were not performed at the initial examination.

The chiropractic examination showed vertebral subluxations upon palpation at C0-C2, C6-T1, T3-5, T9-T10 with a posterior left sacrum at the S1 segment.

The first working diagnosis at that time was of an obstetrical brachial plexus injury with biomechanical dyskinesia (vertebral subluxation complex) around the C0-C2 and C7-T5 areas also involving the shoulder area complex. Other differential diagnosis included complications of consolidated clavicle fracture, a possible cerebral lesion like cerebral palsy or tumor. Two weeks after the first visit, some additionally symptoms were observed and relayed by the mother. The mother noticed that her baby was having some absences during the day followed by some flexor spasms of the neck, mostly when she was tired or upon awakening. The possibility of a cerebral lesion then became the first probable diagnosis. With videos of the spasms of hand, she was then able to see a pediatric neurologist who ordered scans. At 7½ months, the baby girl was diagnosed with West syndrome and spastic hemiplegia caused by a presumed fetal stroke. The ischemic area involved was in the territory of the left middle cerebral artery and the majority of her left parietal lobe was liquefied by the time of diagnosis.

## Interventions and outcomes

After the initial examination of the baby, we made it clear to the mother that co-management of medical and chiropractic professionals was necessary in order to clarify the diagnosis and to gather more facts on the extent of the condition. Fortunately, within three weeks, we received the medical diagnosis and the multidisciplinary approach became essential, optimizing a long-term functional outcome and impacting the brain and nervous system plasticity. In view of the fact that the condition is non-reversible, the management of the baby's condition would consist of follow-ups on a long term basis. Rehabilitation would potentially improve the deficiencies and help the baby develop to the maximum of her potential while simultaneously improving the quality of her life. Given the state of the health care system (Quebec), delays in multidisciplinary referrals are common. Consequently, the chiropractor was the only health care provider working with the patient from the age of 7½ months to 9½ months at which time she was seen by the consulting physician and the multidisciplinary management began.

## Chiropractic management

Initially, we saw the patient twice a week for 6 weeks, once a week for 5 months and then every two weeks for 6 months. Between the ages of 18 months to 28 months, we saw her for adjustments at intervals of 3 to 5 weeks working around the mother's and child's many other associated appointments and interventions.

Chiropractic management started gradually with the application of the following techniques:

- Fascial release to upper and lower extremities; slight mobilization on clavicle, arm, scapula, elbow, wrist and hip joints
- Slight traction of occiput-sacrum in the cephalic direction
- Chiropractic adjustments in the thoracic and sacral regions T2-3, T8-T10 and sacrum (low force manual techniques)
- C1 and C6-7: Activator method in cervical spine or sustained pressure especially C1 on right side in laterality and C6-7
- Low force manual cranial techniques

---

**\*\*Note:** Neither manual nor activator adjustments were delivered to correct the atlas laterality in the first 2 weeks; we decided to proceed with additional cranial work after the diagnosis of a possible fetal stroke while waiting for information on the probable cause(s).

After the initial 6 weeks we added the following:

- Joint mobilizations exercises (mostly arm and hip)
- Stimulation exercises to stimulate right and left hemispheric communication and the vestibular system performed in the clinic and given to the mother to do at home:
  - Frog and spider exercises
  - Contralateral hand to toe touch
  - Hip and arm passive mobilizations
  - Ventral exercises on a roll + gym ball

After the first two weeks of working with the infant, the mother immediately noticed improvement in shoulder mobility through active motion. By helping her with passive stretching and movements, the mother noticed less resistance. Of note, during the first visits, the baby cried simply after being touched or as a result of movement in the shoulder-clavicle-scapula area. This intense crying decreased in the first two weeks. The ROM in the cervical area improved rapidly with less resistance than was present at the outset of the treatment. No adverse effect from any of the treatments provided was reported by the mother.

Two thermal scans were performed (Millenium Insight®) at the ages of 12 and 15 months. Both scans showed hyperactivity of the autonomic nervous system in the upper cervical and the cervicothoracic regions.

## Medical management

Co-management was recommended soon after the initial examination in order to further clarify the diagnosis. During the third week of care, the mother saw a neurologist about the cervical flexion spasms that had now begun: the head was falling into flexion and left lateral flexion with a superior eye-glaze in a cluster-like pattern, mostly when she was waking up. At 7½ month, a brain EEG confirmed hypsarrhythmia patterns typical of infantile spasms\West syndrome related to a possible intrauterine or fetal stroke. Hypsarrhythmia is an abnormal interictal pattern, consisting of high amplitude and irregular waves and spikes in a background of chaotic and disorganized activity seen on electroencephalogram (EEG), frequently encountered in an infant diagnosed with infantile spasms. Blood tests were done at 8 months to confirm a lowered resistance to the C-protein. A cerebral MRI was done at 9½ months and it confirmed a left middle cerebral artery (MCA) lesion that affected most of the parietal lobe. Involvement of the factor V Leiden (FVL) was confirmed at the time for the baby and

the mother also tested positive for the Leiden V factor a few months later. Maternal and neonatal thrombophilia in the presence of FVL has been investigated scientifically in the pathogenesis of perinatal arterial ischemic stroke.

Initial management consisted of controlling the spasms with pharmacological agents. A trial of three different types of medication was run:

- Sabril® (Vigabatrin) was first introduced;
- Lamictal® (Lamitrogine) as a secondary medication;
- The spasms were difficult to control so a third medication was prescribed for epileptic spasms at 12 months: Keppra. XR® (Levetiracetam)

Keppra® was removed after a trial of a few days because the baby was exhibiting side effects (anorexia, insomnia, sudden mood changes and unusual behavior). At that time, the neurologist recommended that the baby undergo surgery to control the epilepsy that was preventing the brain from developing. A functional hemispherectomy was performed on the child at 15½ months. The first two medications were administered for a year following surgery and were gradually eliminated; Sabril® at six months post-surgery and Lamictal® at twelve months.

## Multidisciplinary Approach

In order for the baby to reach maximal function, a multi-disciplinary approach was essential. Since the initial application of chiropractic adjustments and recommendations, several health care professionals were added:

- Physical therapist (conventional and water rehabilitation)
- Occupational therapist
- Speech therapist
- Ophthalmologist
- Neuropsychologist
- Audiologist

At 13½ months, right before surgery, the infants expressive language included the words “mommy and “yes” and nodded her head yes and no. But the seizure activity was so frequent that it was preventing the brain creating and maintaining developing neuronal connections. Subsequent to surgery, motor and developmental improvements were noted. The baby was relating to people more readily; she was more alert, started to babble more and developed both her receptive and expressive language skills. At 20 months

she started sitting unattended. At 27 months, she is still unable to crawl, kneel or roll.

Discussion

Perinatal arterial ischemic stroke (AIS) is defined as a fetal or neonatal cerebrovascular event and is 17 times more common than strokes later in childhood and represents 80% of neonatal strokes<sup>1,2,3</sup> with a recurrence rate of 3-5% in later childhood. Some cases present in the first days of life but many can be delayed in their presentation. Hand preference will assist in establishing a diagnosis of hemiparesis. To complicate matters, in some cases there are no episodes of seizure as in the clinical presentation of our case. Infants presenting neurological signs and seizures (or epilepsy) soon after birth can be diagnosed as early as their stay in the hospital. Because delayed presentations can be revealed first in our chiropractic practices, it is essential that chiropractors be trained to recognize the associated signs and symptoms of AIS (including seizures). Parents typically come to us after having noticed delayed milestones or other early physical or behavioral concerns. The signs and symptoms of AIS are outlined in *Table 1*.<sup>3,9</sup>

Cognitive impairment after a neonatal stroke ranges from 0 to 55% and language delay up to 25%. More than 50% of cortical strokes are located in the middle cerebral artery (MCA) territory with complete and posterior truncal area being more common.<sup>7</sup> Children who suffer a neonatal stroke or infarction in the MCA territory may develop thalamic atrophy but whether this has long-term implications for sensory integration is not clear and difficult to assess in this age group. The incidence of cerebral palsy after perinatal AIS ranges widely, from 6 to 88% according to the literature. Most infants will walk by the age of 2 and will eventually be able to be assimilated into a regular classroom. Only a small percentage will have to undergo surgery for major and intractable epileptic syndromes like West syndrome as in our case study.<sup>12</sup> A study done on 40 children who had suffered perinatal stroke found that the extent of the stroke and injury to any of the a number of regions (Broca's region, the internal capsule, Wernicke's area or basal ganglia) were associated with cerebral palsy.<sup>13</sup> Children who appear normal in the neonatal period but develop a hand preference or have a seizure after 2 months of age as a result of perinatal AIS may have a worse prognosis than children who displayed neurological signs as neonates. In such cases, the presenting hemiparesis is more likely to persist.<sup>13,14</sup> This was also the situation in our case-report.

The causes of perinatal AIS are presently poorly understood. Risk factors for perinatal strokes can be clas-

Early Signs of Perinatal AIS	Delayed Signs and Residual Effects of Perinatal AIS
Focal motor seizures involving one extremity	Early handedness (dominance)
Hypotonia	Hemiparesis
Lethargy	Delayed milestones
Difficulty feeding	Epilepsy/seizure
Apnea	Cognitive and sensory impairments/ Difficulty in visuo-spatial tasks
	Cerebral palsy
	Impaired visual function
	Language delay

Table 1. Signs and symptoms of perinatal arterial ischemic stroke (AIS)

sified under maternal conditions, complications during pregnancy and delivery and fetal conditions as shown in *Table 2*.<sup>1,3,4</sup> It must also be noted that multiple risk factors increase the rate of AIS.

Infantile spasms/West syndrome

West syndrome is described by a characteristic triad of infantile spasms, interruption in psychomotor development and hypsarrythmias. Only 5 to12% of patients exhibit normal mental and motor development, 50% are left with motor impairment and 70 to 78% are mentally challenged.<sup>15</sup> The severe spasms related to this condition are usually resistant to usual seizure medication and the prognosis is poor and associated with increased morbidity because maturation and cognitive development of the brain are affected by the spasms. This category of epileptic encephalopathy responds more favorably to hormonal treatment like ACTH and steroids than conventional antiepileptic medication.<sup>16</sup> However, for some geographic and availability reasons, our case study patient was prescribed Vigabatrin, and ACTH/steroids were never considered by the medical team unlike in many other cases described in the literature.<sup>15-17</sup> Most cases respond well to medication but in some cases, the patients have to undergo surgery for refractory spasms. The favorable outcome of surgical treatment for refractory spasms is well supported in the literature.<sup>10,18</sup> Unfortunately, this was the scenario in this case report which led to major developmental changes in the following 6 to 12 months post-surgery. At this time, the relationship between children

Fetal Risk Factors	Maternal Risk Factors
Cardiac disorders: <ul style="list-style-type: none"> <li>• Congenital heart disease</li> <li>• Patent ductus arteriosus</li> <li>• Pulmonary valve atresia</li> </ul>	Personal/ family history of infertility and risk of thrombosis (prolonged bed rest, surgery, dehydration or shock of any origin)
Coagulation disorders: Blood, homocysteine, and lipid disorders include: <ul style="list-style-type: none"> <li>• Polycythemia</li> <li>• Disseminated intravascular coagulopathy</li> <li>• Factor-V Leiden mutation</li> <li>• Protein-S deficiency</li> <li>• Protein-C deficiency</li> <li>• Prothrombin mutation</li> <li>• Homocysteine</li> <li>• Lipoprotein (a)</li> <li>• Factor VIII</li> </ul>	Chorioamnionitis and placental vasculopathy
Infection: <ul style="list-style-type: none"> <li>• CNS infection</li> <li>• Systemic infection</li> </ul>	Premature/prolonged rupture of membrane
Birth trauma and cauterization procedures	Preeclampsia
Placental Disorders: <ul style="list-style-type: none"> <li>• Placental thrombosis</li> <li>• Placental abruption</li> <li>• Placental infection</li> <li>• Fetomaternal hemorrhage</li> </ul>	Maternal disorders: <ul style="list-style-type: none"> <li>• Autoimmune disorders</li> <li>• Coagulation disorders</li> <li>• Anticardiolipin antibodies</li> <li>• Twin to twin transfusion syndrome</li> <li>• In utero cocaine exposure and infection</li> </ul>
Perinatal asphyxia	Drug abuse (cocaine)
Drugs	Oligohydramnios
Dehydration	
Extracorporeal membrane oxygenation	

**Table 2. Risk factors related to perinatal arterial ischemic stroke (AIS)**

with epilepsy and perinatal AIS is not well understood compared to other pharmaco-responsive epilepsies in the same age group.<sup>19</sup>

### The Factor V Leiden mutation and its relation to perinatal stroke

The factor V Leiden is an autosomal dominant mutation that, genetically, is most commonly related to deep vein thrombosis in children.<sup>20</sup> It is known that the resistance of the factor V Leiden mutation to activated protein C results in increased thrombin generation and a shift towards increased coagulability. Recent literature is not conclusive regarding whether or not the factor V Leiden,

and prothrombin 20210G>A, can be related to arterial ischemic stroke.<sup>19</sup> It may be a factor but cannot contribute alone to the development of the condition. In presumed pre- or perinatal arterial ischemic stroke, coagulopathies in the fetus or infant and maternal/ infant thrombophilia may be important in the etiology of infarcts. Anticardiolipin antibody (ACLA) and Antiphospholipid antibody, even if the role is unclear, may also be a major player in these strokes.<sup>14,21</sup>

### Financial impact

The average 5-year cost of treating neonatal stroke in a 2010 study,<sup>22</sup> after adjustments for control costs, was



approximately \$50,000 USD. That study found that the financial burden of strokes in neonates and children is both substantial and long term, and increases the cost of health care over five years 15-fold compared to age-matched children who have not suffered a stroke. The birth admission costs for patients with presumed perinatal strokes, even if diagnosed later, still exceeds those of stroke-free controls by an average of almost \$7,000 USD, suggesting that these children have greater medical needs in the perinatal period, prior to diagnosis.

### Chiropractic management of infantile strokes

In the chiropractic profession, one study showed improvement in paraspinal muscle tone for four children with cerebral palsy and resulted in the improvement of their daily lives including mobility, feeding, and postural control.<sup>23</sup> Besides the benefits of chiropractic care for children with cerebral palsy, there is still nothing specific pertaining to chiropractic and infantile stroke in the current literature. Healthcare professionals need to collaborate on therapies and interventions for infants with neonatal strokes because, besides acute intervention, not much is available in terms of medical management.

### Case-related speculation

In our case, it is difficult to speculate on the real cause of the perinatal arterial ischemic stroke. Medical specialists do not agree on the actual causes. The presence of genetic factors and coagulation risk factors were probable, but at this time it is difficult to conclude whether or not they were related to the factor V Leiden because of the arterial nature of the stroke. Many factors led to this patient's poor prognosis: she showed late symptoms with severe hemiparesis and infantile spasms; she was resistant to the medication and the seizure activity was progressing despite trials of several medications. Due to this patients' very poor prognosis, cranial surgery was required to optimize long-term functional outcome. The mother saw immediate improvement after chiropractic adjustments but because of the severity of the situation, we could not assess the effectiveness of the chiropractic interventions on their own. Without documented outcomes of previous cases, the late diagnosis reduced the window of time within which it felt responsible to work alone and referral for collaborative care was made. In such a case, known as a non-reversible severe condition, a multi-disciplinary approach proved essential to realize maximal improvement. The major limitation of this study was the difficulty in isolating each professional intervention and its individual effects on the outcome.

### Brain plasticity

Many studies show a greater potential for improvement in the long-term outcome for infants and children when compared to adults because of the greater brain plasticity of the young brain.<sup>24</sup> A study done in 2007 suggests that spinal manipulation of dysfunctional joints may modify transmission in neuronal circuitries not only at a spinal level but also but at a cortical level and possibly also in the deeper brain structures such as the basal ganglia.<sup>24-27</sup> In view of the fact that chiropractors have an impact on brain plasticity, future studies should be undertaken to gain further knowledge and understanding of the causes, diagnosis and treatment of perinatal strokes.

### Conclusion

Knowing that 40% of the infants who are later diagnosed with perinatal stroke do not have specific symptoms in the neonatal period and that they are recognized only later with the emergence of breastfeeding problems, motor impairment, developmental delays and specific cognitive deficiencies or seizures, chiropractors may see many of these infants and young children in their practices.

Even as stroke in infants is increasingly being recognized as a serious neurological disorder that places a major financial burden on parents and the government, limitations in knowledge and awareness have hampered its recognitions among the population and health care professionals including chiropractors. Late diagnosis limits the opportunities for timely interventions that could improve the functional outcome and impact the quality of life of the patients and their families. As primary health care providers who play a major role in diagnosing and treating this condition, chiropractors should have the skills needed to detect its early signs so that they can then make the proper and necessary timely referrals. Guidelines for treatment are limited in the current literature and there is no current consensus. More research needs to be done to understand the pathophysiological mechanisms, the risk factors and clinical interventions that lead to an improved outcome. Ongoing and future multidisciplinary cooperative studies, which include chiropractors, are necessary in order to establish comprehensive evidence-based guidelines for the rehabilitation of perinatal stroke. Knowing that the young brain has a strong potential for neuronal plasticity, the chiropractic profession need to demonstrate how adjustments have a major impact on brain plasticity and how they can improve the long-term outcome for their patients. This subject is one of importance for future years.

## References

1. Mackay MT, Gordon A. Stroke in children. *Australian Family Physician* 2007, 36(11), 896-902.
2. Lynch JK, Nelson KB. Epidemiology of perinatal stroke. *Current Opinion In Pediatrics* 2001, 13(6), 499-505.
3. Nelson KB, Lynch JK. Stroke in newborn infants. *Lancet Neurology* 2004, 3(3), 150-158.
4. Chabrier S, Husson B, Dinomais M, Landrieu P, Nguyen The-Tich S. New insights (and new interrogations) in perinatal arterial ischemic stroke. *Thrombosis Research* 2011, 127(1), 13-22.
5. Raju TNK, Nelson KB, Ferriero D, Lynch JK. Ischemic perinatal stroke: summary of a workshop sponsored by the National Institute of Child Health and Human Development and the National Institute of Neurological Disorders and Stroke. *Pediatrics* 2007, 120(3), 609-616.
6. Feekes JA, Hsu S-W, Chaloupka JC, Cassell MD. Tertiary microvascular territories define lacunar infarcts in the basal ganglia. *Annals Of Neurology* 2005, 58(1), 18-30.
7. Govaert P, Ramenghi L, Taal R, de Vries L, deVeber G. Diagnosis of perinatal stroke I : definitions, differenteial diagnosis and registration (review article). *Acta Paediatrica* 2009, 98, 1556-1567.
8. Roach ES, Golomb MR, Adams R, Biller J, Daniels S, DeVeber G., et al. Management of stroke in infants and children: a scientific statement from a Special Writing Group of the American Heart Association Stroke Council and the Council on Cardiovascular Disease in the Young. *Stroke; A Journal Of Cerebral Circulation* 2008, 39(9), 2644-2691.
9. Wu YW, Lynch JK, Nelson KB. Perinatal arterial stroke: understanding mechanisms and outcomes. *Seminars In Neurology* 2005, 25(4), 424-434.
10. Marras CE, Granata T, Franzini A, Freri E, Villani F, Casazza M, et al. Hemispherotomy and functional hemispherectomy: indications and outcome. *Epilepsy Research* 2010, 89(1), 104-112.
11. Lynch JK. Cerebrovascular disorders in children. *Current Neurology and Neuroscience Reports* 2004, 4(2), 129-138.
12. Shields WD, Shewmon DA, Chugani HT, Peacock WJ. Treatment of infantile spasms: medical or surgical? *Epilepsia* 1992, 33 Suppl 4, S26-S31.
13. Lee J, Croen LA, Lindan C, Nash KB, Yoshida CK, Ferriero DM, Wu YW. Predictors of outcome in perinatal arterial stroke: a population-based study. *Annals Of Neurology* 2005, 58(2), 303-308.
14. Golomb MR, MacGregor DL, Dom T, Armstrong DC, McCrindle BW, Mayank S, deVeber GA. Presumed pre- or perinatal arterial ischemic stroke: risk factors and outcomes. *Annals Of Neurology* 2001, 50(2), 163-168.
15. Sharma NL, Vishwanthan V. Outcome in West syndrome. *Indian Pediatrics* 2008, 45(7), 559-563.
16. Jaseja H. Justification of vigabatrin administration in West syndrome patients? Warranting a re-consideration for improvement in their quality of life. *Clinical Neurology And Neurosurgery* 2009, 111(2), 111-114.
17. Gupta R, Appleton R. Corticosteroids in the management of the paediatric epilepsies. *Archives Of Disease In Childhood* 2005, 90(4), 379-384.
18. Jonas R, Asarnow RF, LoPresti C, Yudovin S, Koh S, Wu JY, Mathern GW. Surgery for symptomatic infant-onset epileptic encephalopathy with and without infantile spasms. *Neurology* 2005, 64(4), 746-750.
19. Laugesaar R, Kahre T, Kolk A, Uustalu U, Kool P, Talvik T. Factor V Leiden and prothrombin 20210G>A [corrected] mutation and paediatric ischaemic stroke: a case-control study and two meta-analyses. *Acta Paediatrica* 2010 (Oslo, Norway: 1992), 99(8), 1168-1174.
20. Lynch JK, Nelson KB, Curry CJ, Grether J K. Cerebrovascular disorders in children with the factor V Leiden mutation. *Journal of Child Neurology* 2001, 16(10), 735-744.
21. Simchen MJ, Goldstein G, Lubetsky A, Strauss T, Schiff E, Kenet G. Factor V Leiden and Antiphospholipid Antibody in either mother or infants increase the risk for perinatal arterial ischemic stroke. *Stroke* 2009, 40:65-70.
22. Gardner MA, Hills NK, Sidney S, Johnston SC, Fullerton HJ. The 5-year direct medical cost of neonatal and childhood stroke in a population-based cohort. *Neurology* 2010, 74(5), 372-378.
23. Matthew M, Ekaterina M, Yuri S, Christopher K, & Peter S. Improvement in Paraspinal Muscle Tone, Autonomic Function and Quality of Life in Four Children with Cerebral Palsy Undergoing Subluxation Based Chiropractic Care. *Journal of Vertebral Subluxation Research* 2006, 1-15
24. Haavik-Taylor H, Murphy B. Cervical spine manipulation alters sensorimotor integration: a somatosensory evoked potential study. *Clinical Neurophysiology: Official Journal Of The International Federation Of Clinical Neurophysiology* 2007, 118(2), 391-402.
25. Herzog W. Mechanical, Physiologic, and Neuromuscular Considerations of Chiropractic Treatments. In: Lawrence DJ, Cassidy JD, McGregor M, Meeker WC, Vernon HT (Eds.), *Advances in Chiropractic* 1996, pp. 269-285. St. Louis: Mosby-Year Book, Inc.
26. Murphy BA, Dawson NJ, Slack JR. Sacroiliac joint manipulation decreases the H-reflex. *Electromyography And Clinical Neurophysiology* 1995, 35(2), 87-94.
27. Symons BP, Herzog W, Leonard T, Nguyen H. Reflex responses associated with activator treatment. *Journal Of Manipulative And Physiological Therapeutics* 2000, 23(3), 155-159.



# Chiropractic Management of Adductor Muscle Strain

Stephanie Willis, BAppSc(ClinSc)/BChiroSc, DICCP, CCWP

## ABSTRACT

**Objective:** To describe the successful management of a young female diagnosed with thigh adductor muscle strain and its association to pelvic subluxation.

**Clinical Features:** A 7-year-old female sought chiropractic care for the management of adductor muscle strain of her right thigh, which prevented her from performing passive full thigh abduction. She was also experiencing pain during right thigh abduction at the proximal attachment of the right thigh adductor group, just distal to the pubic bone. The patient is involved in competitive dance, and has a very physically active lifestyle.

**Intervention and Outcome:** Sacro Occipital Technic (SOT) chiropractic analysis and adjusting, Activator® instrument adjusting, as well as trigger point therapy, effleurage, Proprioceptive Neuromuscular Facilitation (PNF) and dynamic stretching of the adductor muscles of the right thigh were administered over 2 visits. Thigh abduction range of motion, pain at end abduction range of motion, adductor muscle hypertonicity, pain on palpation of adductor musculature and pain in the adductor musculature with manual muscle testing were the criteria by which the outcome was assessed. Symptoms were reported as completely resolved immediately following the second adjustment. By the second treatment, the patient was able to fully abduct the previously painful thigh and perform previously affected functional movements in the absence of pain or dysfunction.

**Conclusions:** A young girl with right thigh adductor strain experienced improvement following 2 chiropractic treatments, however soft tissue technique was employed in addition to chiropractic adjustments. Future research should be conducted to investigate the role of chiropractic adjustments in the treatment of adductor muscle strain.

## Introduction

Adductor injury, including adductor strain, has an incidence of involvement in 2-5% of all sporting injuries, and are most commonly observed in athletes who are required to perform repetitive movements.<sup>1,2</sup> According to Avrahami & Choudur<sup>1</sup>, there are many possible causes of adductor pain, which include stress on the symphysis pubis, and sacroiliac subluxation. The prevalence of adductor strain is unknown within the pediatric population.

The purpose of this paper is to describe the case of a young competitive dancer, who demonstrated thigh adductor strain improvement while under chiropractic care, and to discuss the features of adductor sprain, including relevant anatomy, natural history, and the theory as to why chiropractic care may assist in healing.

## History

A 7-year-old female sought chiropractic care for pain with activity and associated restricted abduction of her right thigh. She is a competitive dancer, and stated that

she participates in vigorous physical activity most days. She reported that her pain began 4 weeks prior to seeking care, and progressed gradually during a day of dance and exercise, but not from any one specific activity. The patient stated that she had not suffered from this condition previously. Prior to presenting to the chiropractic office, she sought care from her primary care physician, who prescribed rest from all activity. The patient also stated that she suffers from a moderate scoliosis, which forms an "S" shaped curve through her spine. On physical examination this was confirmed as a lumbar levoscoliosis and a thoracic dextroscoliosis. No x-rays were taken.

## Examination

Physical examination revealed a decrease in passive right thigh abduction by approximately 30 degrees, due to moderate pain that the patient reported slightly distal to the pubic symphysis; the location of thigh adductor musculature attachment. Right hip flexion also reproduced pain near the adductor muscle group attachment site upon reaching end-range hip flexion.

Right thigh adductor musculature was moderately hypertonic and elicited moderate palpatory tenderness. Manual muscle testing of the adductor group revealed moderate tenderness in the area of the adductor group

---

*Stephanie Willis, BAppSc(ClinSc)/BChiroSc, DICCP, CCWP*  
Private practice, Canterbury, Victoria, Australia  
Email: [info@inspirechiropractic.com.au](mailto:info@inspirechiropractic.com.au)

muscle attachment to the pubic bone. Sensory examination was within normal limits, however, the patient reported moderate pain near the right side of the pubic symphysis upon motor examination of her right thigh adductors. Palpation revealed moderate tenderness at the superior aspect of the medial portion of the right pubic bone, and motion palpation revealed decreased motion in a superior to inferior direction of the distal portion of the right pubic bone. Sacro Occipital Technic (SOT) analysis revealed a Category I distortion<sup>3</sup> of the right sacroiliac joint, and the right leg measured shorter than the left by approximately 5mm upon prone evaluation of leg length.

## Diagnosis

Diagnosis was mild subacute right thigh adductor muscle strain, with concurrent subluxation of the pelvis with SOT Category I right sacroiliac joint involvement and a right functional short leg.

## Intervention And Outcome

SOT adjusting procedure, which employs small foam wedges to reposition the pelvic joints, was used to adjust the SOT right Category I subluxation,<sup>3</sup> and the superior right pubic bone was adjusted using an Activator<sup>®</sup> instrument. Both effleurage and trigger point therapy were employed to reduce the hypertonia in the right thigh adductor musculature, and these two techniques were primarily utilized through the adductor magnus, adductor longus and gracilis muscles. The proximal portion of each of these muscles was the area through which this therapy was concentrated. The trigger point therapy was focused through several points in this proximal adductor region, with each point being held for approximately

one minute with ischemic pressure. Effleurage was performed through the same area as the trigger point therapy, in a distal to proximal direction, and was performed for several minutes. Both static and dynamic stretching, including PNF, were also administered to the right thigh adductor group, and the patient was encouraged to continue these stretches at home until her next visit.

Post-adjustment range of motion testing of the involved thigh demonstrated restoration of full range of motion in all directions. However, the patient reported mild pain upon end-range right thigh abduction at the proximal portion of the common adductor group tendon, just distal to its attachment to the right pubic bone. In addition, the muscles still displayed mild hypertonicity, mild pain on palpation and mild pain with manual muscle testing. A follow-up evaluation was scheduled for 2 weeks.

The patient returned for reevaluation, and reported that she was still experiencing mild pain with abduction end-range motion. The patient was again evaluated using joint play and pain findings associated with the pubic bone to assess the position and function of the pubic bone. The pubic bone displayed mild pain findings at the superior aspect, just lateral to the symphysis pubis, and continued to demonstrate decreased joint play in a superior to inferior motion of the right pubic bone. The adductor muscles palpated with mild myotonicity, and palpation elicited mild pain. Manual muscle testing of the right adductor group elicited mild pain at the proximal portion of the muscle group. The pelvis was analyzed, using SOT protocols, and the SOT Category I subluxation remained.

	Pre 1st adjustment	Post 1st adjustment	Pre 2nd adjustment	Post 2nd adjustment
<b>Abduction ROM</b>	Decreased approximately 30°	Full	Full	Full
<b>Pain at end ROM</b>	Moderate	Mild	Mild	Nil
<b>Muscle hypertonicity</b>	Moderate	Mild	Mild	Nil
<b>Pain on palpation</b>	Moderate	Mild	Mild	Nil
<b>Pain with muscle test</b>	Moderate	Mild	Mild	Nil

**Table 1. Results from 5 areas of clinical assessment demonstrating patient improvement over 2 treatments**



Following the examination, the patient received treatment which included the same elements as the initial treatment.

Immediately following the second treatment, the patient reported no pain or dysfunction. Assessment of range of motion demonstrated full range of motion in thigh abduction with no pain. Manual muscle testing of the adductor group revealed no pain, and the muscle palpated without hypertonicity. The patient's mother contacted the doctor 2 weeks following the second treatment, and reported that her daughter remained symptom-free and had returned to full participation in her dance & exercise regime.

### Discussion

The musculoskeletal system of a competitive dancer endures a high level of strain, and injuries may ensue. Chiropractic is a treatment option for such injuries, and the use of chiropractic care for the management of physical injuries has been reported as beneficial for decades.<sup>4</sup> While chiropractors commonly treat patients with adductor strain,<sup>5</sup> there remains an absence of information to support effectiveness of this treatment.<sup>6</sup>

The adductor muscle group of the thigh, consisting of adductor magnus, adductor longus, adductor brevis, pectineus and gracilis, attaches proximally into the pubic bone.<sup>7</sup> These muscles receive their innervation from the obturator nerve, which is composed of nerve fibers originating from the lumbar nerve plexus, specifically from the spinal levels L2-4, and receive their blood supply from the posterior branch of the obturator artery.<sup>7</sup> The thigh adductors are a powerful group of muscles, and compromise to their integrity may result in motion restrictions and painful movement of the leg.

Adductor strain usually follows a natural history of 2-3 days of acute pain, followed by 6-8 weeks of restricted motion and tissue reconstruction, during which time new collagen is laid down and the integrity of the involved structures is restored, and finally several months of rehabilitation, during which time the tissue can regain its original integrity and strength. Beneficial treatments utilized for this patient include ice massage, chiropractic adjustments, active and passive stretching and massage. According to Robb & Pajackowski (2010), any soft tissue injury that is managed inefficiently may lead to scar tissue formation, resulting in disability and chronicity of the condition.<sup>8</sup>

Chiropractic theory proposes that chiropractic adjustments of the pelvis may aid in the resolution of an adductor

injury. This is thought to be the result of reestablishing a proper biomechanical relationship of the pelvis and surrounding musculature, which may accelerate the typical healing process of soft tissue injuries.<sup>9</sup> By addressing the structural balance of the pelvis, the adductor muscles may be more likely to function with equal strength and stability, restoring full range of motion without pain to the adductor musculature.<sup>9,10</sup> SOT3 is a chiropractic technique that uses low force adjustments in order to influence the alignment of the pelvis, with the goal of improving function of the spine and related structures; this was the adjusting technique utilized for this case.

In this case, the patient did not seek chiropractic care until 4 weeks post-injury, and it was important to minimize tissue damage by using effleurage, PNF and stretching. Restoring balance to the pelvis was an important part of the management of this case; however using adjunctive techniques such as those mentioned above, as well as chiropractic adjustments, ensured the effective management of an adductor strain.

Unfortunately, no set protocol for the management of adductor strain exists. Several articles demonstrate the use of various interventions, however none state that there is a set treatment plan that one should follow.<sup>1,5,6,8,11,12</sup> This work demonstrates a framework was successful for the management of adductor muscle strain.

### Conclusions

This case demonstrates the successful management of a patient in a chiropractic office, receiving a combination of chiropractic adjustments and soft tissue techniques. Although it cannot be demonstrated which specific part of the employed treatment was directly responsible for the patient's improvement, it is the author's contention that the combination of the various treatment modalities is what resulted in the patient's improvement. This work demonstrates that chiropractic may have a role in the treatment of adductor muscle strain, however more research should be conducted to explore the sole merits of chiropractic in this clinical scenario.

**Authors' Contributions:** Dr. Stephanie A. Willis conceived the report, conducted the initial review of the case, and contributed to numerous drafts of the manuscript. Dr. Christopher B. Roecker contributed to outline, content, and editing of numerous manuscript drafts.

### References

1. Avrahami D & Choudur HN. Adductor tendinopathy in a hockey player with persistent groin pain: a case report. *JCCA* 2010; 54(4):264-70.

2. Micheo W. Musculoskeletal, Sports, and Occupational Medicine. Demos Medical Publishing; 2010.
3. Howat J. Chiropractic Anatomy and Physiology of Sacro Occipital Technique. Cranial Communications Systems; 1999.
4. Schafer RC. Chiropractic Management of Sports and Recreational Injuries. Baltimore: Williams & Wilkins;1982.
5. Spencer, JE. Groin Strain: Chiropractic Rehabilitation. *J Bodyw Mov Ther* 1998; 2(3):154-60.
6. Horrigan J. Resolution of a Groin Injury in a Professional Hockey Player by Soft Tissue Mobilization: A Case Report. *Chiro Sports Med* 1992; 6(4): 151-4.
7. Gray H. Gray's Anatomy. Philadelphia: Churchill Livingstone; 2008.
8. Robb A, Pajaczkowski J. Immediate effect on pain thresholds using active release technique on adductor strains: Pilot study. *J Bodyw Mov Ther* 2011;15(1): 57-62.
9. Seaman DR. Dysafferentation: a novel term to describe the neuropathophysiological effects of joint complex dysfunction. A look at likely mechanisms of symptom generation. *JMPT* 1998; 21(4).
10. Gatterman, M.I. Foundations of Chiropractic: Subluxation. St. Louis: Mosby-Year Book, Inc; 1995.
11. Krüger-Franke M. Traumatische Muskel und Sehnenrupturen der unteren Extremität beim: Adduktoren, M. biceps femoris und M. rectus femoris. (Sport Traumatic muscle and tendon ruptures of the lower extremities in sport: Adductor muscles, m. rectus femoris and m. biceps femoris). *M Der Orthopäde* 2010; 39(12) :1123-6.
12. Mens J et al. A New View on Adduction-Related Groin Pain *Clin J Sport Med* 2006;16(1):15-9.



# Resolution of Delayed Motor Milestones and Abnormal Primitive Reflexes in an 8-Month-Old Full Term Infant Following Chiropractic Care

Donna M. Quezada, DC, BS, DICCP, DIBCN and Andrea Haan, DC, MS

## ABSTRACT

**Objective:** The objective of this case report is to discuss the clinical course of an 8-month-old male who presented to a chiropractor for well care, and upon examination, displayed delayed gross motor milestones and abnormal primitive and postural reflexes.

**Clinical features:** An 8-month-old male child presented to the chiropractic office for a routine well care evaluation. During the examination, the infant displayed an inability to sit unsupported, difficulty in holding his head up or supporting his upper body on his forearms while prone, and an asymmetrical, poorly executed belly crawl. Certain primitive reflexes, were retained past the age of normal integration, and the Landau postural reflex was poorly executed past the age of emergence.

**Intervention and outcome:** Seven full spine and craniosacral chiropractic adjustments were given to the infant over the next 24 days, with a follow-up visit 6.5 months after the final corrective phase visit. The mother complied with exercising the infant by implementing a home exercise program. The infant's noted deficits were improved following this 24-day course of care, as measured by report from the mother, and examiner observation and evaluation. His motor skills and milestones normalized, and upon evaluation by the examiner seven months later, were ahead of expected development.

**Conclusions:** Infants with certain delayed milestones and retained infantile reflexes may benefit from chiropractic adjustments and rehabilitative exercises. Further studies assessing the relationship between neurologic soft signs, chiropractic care, and neurologic soft sign symptom resolution should be done to determine if correcting these abnormal signs helps to reduce the incidence or severity of certain neurologic disorders.

**Key Words:** chiropractic, developmental motor milestones, primitive reflexes, spinal adjustment, craniosacral therapy, full-term infant

## Introduction

During the first two years of life, proper development of gross, fine, and oral motor skills is essential to the overall and continued development of an infant. Nutritional intake and physical growth rely on the infant developing appropriate self-feeding skills<sup>1</sup> while walking, crawling, sitting and standing require developing strength, balance, and coordination.<sup>2</sup> As the infant grows, retained infantile reflexes and delayed developmental milestones (*Table 1*) may be prognostic of prolonged bed-wetting,<sup>3</sup> a later diagnosis on the autism spectrum,<sup>4,5</sup> chronic brain syndromes,<sup>6</sup> Cerebral Palsy, or developmental retardation.<sup>7,8</sup> Depression and anxiety at school age,<sup>9</sup> sensory integration disorders<sup>10</sup> and long term effects on cognitive function<sup>11-13</sup> have also been associated with delayed motor development. Therefore, assessment of an infant's primitive reflexes and

developmental milestones comprise the earliest, simplest, and most frequently used tools to assess infant central nervous system integrity.<sup>8</sup>

Primitive reflexes develop in utero commencing as early as the 25th week of gestation and are fully present at birth in full term infants (*Table 2*). They are brainstem-mediated, complex, automatic movement patterns elicited by specific sensory stimuli and are considered part of the motor repertoire of a specific age. With central nervous system maturation, the primitive reflexes become more and more difficult to elicit after the first six months of life. It is at this time that voluntary motor activity and cortical inhibition emerge and dominate motor control<sup>8</sup> and the postural reflexes develop.<sup>15</sup>

The purpose of this case report is to discuss the clinical course of a full-term, 8-month-old infant who presented with delayed developmental motor milestones to the 3 month level and with the retained primitive reflexes of the palmer grasp, placing response, and Galant's reflex, along with delayed emergence of the Landau postural reflex.

**Donna M. Quezada, DC, BS, DICCP, DIBCN**

Private practice: Enumclaw, WA 98022

Email: drdonnaq@clearwire.net

**Andrea Haan, DC, MS**

Palmer College of Chiropractic, Davenport, Iowa

Age of Appearance	Milestone	Notes	This infant on initial examination
<b>3 Months</b>	While prone, is able to lift head and shoulders and support himself by the forearms.	May have to be placed in this position. Should be able to maintain position for a period of time.	Difficulty maintaining: head drooped and right side slumped.
<b>6 Months</b>	Sit without support	Sitting without support is defined as sitting erect (not leaning forward) for 10 to 60 seconds without using his arms or other means of external support. A toy is often given to the infant to occupy his hands. <sup>7,21</sup>	Sat for less than 5 seconds with head and trunk slumped in hypotonus then fell slowly to his side.
<b>6 Months</b>	While prone, is able to support his head and shoulders with extended arms. <sup>15</sup>	Should be able to hold this position for 10 to 60 seconds.	Minimally supported his head and shoulders on his elbows.
<b>6 Months</b>	Belly Crawl	Infant moves forward with their belly touching the ground: either Commando or inch worm fashion. <sup>22</sup>	Commando crawl was poorly executed, predominantly using the left limbs.
<b>6-9 Months</b>	Progress through the stages of crawling ( <i>see note</i> )	Belly crawl, Rocking on hands and knees, Disorganized hands and knees crawling, Organized hands and knees cross crawling. <sup>21,22</sup>	Was not progressing in proficiency. At 8 months, should have progressed to disorganized hands and knees crawling.
<b>9 Months</b>	Hands and knees (cross) crawl <sup>22</sup>	Locomotion while on palms and knees using alternating movement of upper and lower limbs: the right arm and left leg move forward or backward together or vice versa.	Could not perform on initial examination.

**Note:** Approximately 4-5% of children skip some or all of the stages of crawling and some researchers believe this by itself is not reason for concern.<sup>21,22</sup> However, in the presence of retained primitive reflexes, abnormal postural reflexes or delayed motor milestones, there is cause for concern.<sup>3-7,9-13</sup>

**Table 1. Developmental Milestones**

## Clinical Presentation

### History

The mother brought her 8-month old male infant into the office for his first chiropractic well care examination. She reported this as her first pregnancy and provided the history.

The infant presented in a posterior position (“sunny-side-up”) with APGAR scores of 9 and 10 at 1 and 5 minutes respectively with no reported complications. The 7 lb, 21.75 inch infant received routine in-hospital vaccinations and was discharged with the mother the next day.

The mother reported that during the first two months after birth, the infant slept for 30 minutes during the day between feeds and 3 hours at night. He fell asleep easily

when being breast fed, but spit-up frequently after feeding. He did not have a preferred sleeping position and his mother chose to place him on his back or side.

At 8 months, the infant was still breastfeeding and was eating solid foods. He enjoyed fruits, vegetables, and chicken.

The mother denied the infant experiencing any traumatic events or injury. His health history was remarkable for a minor cold and acute otitis media at age 7 months, for which he was prescribed antibiotics. Routine childhood vaccinations were current with the next series due at 9 months.

The mother reported that the infant, at 8 months of age, was not able to sit unsupported and had difficulty



Name of Reflex	Ages of Onset and Integration	Procedure	Normal Response
<b>Palmer Grasp</b>	Present at birth Gradually diminishes by 6 months	The examiner places her finger into the infant's palm.	The infant's hand closes over the examiner's finger automatically with a strong enough grip for the examiner to lift the infant's torso from the couch. <sup>14</sup>
<b>Placing Response</b>	Present at birth Disappears around 6 weeks	The infant is held upright around the torso. The top of his feet are brushed against the under edge of a surface such as the examining table.	The infant should flex the knees and bring the first touched foot up onto the surface and then the other. <sup>14-16</sup>
<b>Galant's Test</b>	Present at birth Disappears by 4-5 months.	The examiner suspends the infant in a prone position with her hand under his belly. She strokes the infant's back from the shoulder to the buttocks on one side then the other approximately one inch lateral to the spinous processes.	The infant's trunk should flex to the side of the stimulus. The response should be definitive and equal bilaterally. <sup>8,14-16</sup>
<b>Landau Reflex</b>	Manifests by 3-5 months. Persists until about 18 months	Infant position is the same as for Galant's Test. After observing the infant's initial response, the examiner pushes the head into flexion, observes the infant's response, then releases the head.	Initially, the infant's head should extend above the plane of the trunk. With head flexion, the legs should also flex. When the head is released, the infant's head and legs should automatically return to an extended position. <sup>15</sup>  This postural reflex is essential for independent sitting and walking. <sup>17</sup>

**Table 2. Primitive and postural reflexes**

holding his head up or supporting his upper body on his forearms (*see Table 1*). The mother questioned whether his “commando crawl”, which began during the seventh month and continued with difficulty, was normal. All other developmental milestones were met during their expected time frame.

Additionally, the mother reported that a few days before bringing her son in for the chiropractic examination, as she picked her son up she heard his back “pop” and that his wrists used to “pop” frequently.

### Examination

On physical examination, the infant measured 29 inches long and weighed 19 pounds 11 ounces. When the infant sat with support, his neck and trunk slumped (hypotonia) and he could not sit without support for 5 seconds. He cooperatively demonstrated his asymmetric commando crawl, which was poorly executed (although he'd been doing it for one month). He demonstrated a definitive left hand preference. Passive movement elicited crepitus in the infant's wrists and a “click” in the right elbow. Notable primitive reflexes included retention of the palmer

grasp reflex, placing response, and Galant's test, as well as a poorly executed Landau postural reflex.

Spinal subluxations were present in multiple regions: a descended right occiput, C1 anterior arch superior, right posterior arch, C7 posterior right, T5 posterior left, and T10 posterior left. These were identified by evaluation of spinal posture, muscle tone, soft tissue texture, vertebral alignment, intervertebral segmental motion, and gross ranges of motion.

During the cranial examination, an oblique shaped head with a flat spot located on the right occiput was observed. In addition, the frontal, parietal, temporal, palatine, and occipital bones demonstrated misalignment by the presence of decreased passive motion, restricted cranial rhythm, and an elevated palate. The sphenoid bones and the temporomandibular joints were not examined on initial examination due to the infant's unwillingness.

### Intervention and Outcome

Chiropractic adjustments were administered on each visit using diversified and SOT techniques modified for an

Purpose of Exercise	Procedure	Frequency
To augment craniosacral therapy	Stroke the infant's head always toward the flat spot	As often as the infant will allow until the cranium reaches maximum improvement. <sup>20</sup>
To aid independent sitting	Do not let the infant remain passive in a supported seated position for prolonged periods of time. Place the infant in an uncontained seated position repetitively throughout the day. Keep infant from toppling, using as little support as possible, while he attempts to stay upright for 1-5 minutes.	The time infant sits unsupported is gradually increased until infant is able to reach for presented toys, sit and play with them without support, and intentionally move himself to a new posture. <sup>7,21</sup>
To increase arm strength	Hand the infant increasingly heavier toys while he is sitting or lying on his back. Play a tugging game with infant by matching pulling to his resistance.	Repetitively throughout the day.**
To assist the infant's crawling development	Place a sling around the infant's abdomen and hold it above the infant's back, allowing the infant to use as much of his strength as possible to crawl on all fours.*	Repetitively throughout the day.**

\*The infant in this case rejected the sling so the mother substituted using her hands.

\*\*Exercises should be performed until the infant attains age appropriate milestones and reflexes.

**Table 3. Home exercise therapy**

infant's anatomy and physiology. In the cervical spine, when using the Diversified technique, the spinous processes and articular pillars were used for contact. When using SOT, the stair-step protocol was administered. In the thoracic spine, the point of contact was either the spinous process or the transverse process. In the lumbar spine, either the spinous or mamillary processes were contacted. The sacral tubercles were used for each subluxated sacral segment. In all areas of the spine, the adjustments administered used low amplitude short lever thrusts with specific lines of drive. Cranial techniques included those taught by Dr. Carol Phillips,<sup>23</sup> Dr. Major Bertrand De Jarnette,<sup>23</sup> and Dr. Justine Dobson.<sup>20</sup>

The infant received 7 cranial and 5 spinal adjustments over a 24 day period, 2 to 7 days apart (*Table 4*). Extremity adjustments were made to the right elbow and both wrists on the first visit. Extremity adjustments were not indicated at subsequent visits. In addition to the chiropractic adjustments, the mother was given instructions for exercising her son between visits (*Table 3*).

On the day of his second adjustment (*see Table 4*), following two days of exercises, the mother reported that the infant did an upper body push-up for the first time.

Five days later, on the date of the infant's third chi-

ropractic visit (*Table 4*), the mother reported that her son was having bowel movements more frequently and without screaming in pain. She did not report this symptom during the original history. On examination, the infant sat with only mild instability and, when placed on his stomach, was able to push his head and shoulders up and support them with his arms extended. The mother reported performing the prescribed exercises daily, spending approximately ninety minutes per day exercising her son. As a result of the craniosacral therapy and the mother repeatedly stroking the head toward the flat spot, there was a noticeable change in the head shape. It was now more oval, less oblique.

Ten days following initial presentation to the chiropractor, the infant presented for his fourth chiropractic visit and adjustment (*Table 4*) slightly irritable. The irritability was thought to be associated with teething. At this visit, the mother reported that her son was able to pass gas with more ease and less discomfort. Examination revealed that C2 was lateral left with tenderness on the left. T8, 9, and 10 were each spinous process rotated right, and L3 was spinous process rotated left. Cranial subluxations were present in the frontal, sphenoid, parietal, temporal, and occipital bones. The arch of the palate was improved with no detectible abnormality.

Four days later, the infant sat unsupported, and demon-

## Resolution of Delayed Motor Milestones and Abnormal Primitive Reflexes in an 8-Month-Old Full Term Infant Following Chiropractic Care

Day	Services	Subluxations	Adjustments	Outcomes
1	Examination and adjustment	Occiput right low, C1 anterior superior right posterior (ASRP), C7 posterior right (PR), T5 posterior left (PL) T10 PL, Occipitosacral (OS) imbalance.	Diversified (Div.), Sacrooccipital Technique (SOT), Craniosacral balance maneuver (CSBM)	
3	Examination and adjustment	Frontal (F), Parietal (P), Temporal (T), Occipital (O) restrictions. O-S imbalance.	CSBM	First upper body push-up
8	Examination and adjustment	C2PR, T10PR, F,P,T,O, Palate (Pa)	Div., Cranial (Cr)	Improved bowel movements Improved head shape Able to: Support upper body on extended arms when prone. Sit with mild instability
10	Examination and adjustment	C2 Lateral left (LatL), T8PR, T9PR, T10PR, L3PL, F, Sphenoid (S), P, T, O.	Div., Cr	Passes gas without discomfort, Palate arch improved
14	Examination and adjustment	C2LatL, F, P, T, O.	Div., Cr	Sits unsupported, more proficient Commando crawl, Hands and knees crawl with assistance
21	Examination and adjustment	C2LatL, S, P, T, O	Div., Cr	Prolonged sitting without assistance, Obtains hands and knees position, Crawls on forearms and knees, Daily bowel movements, Does High-5's
24	Examination and adjustment	S, T, O with right occiput inferior	Cr	Milestones Current
Followup	Examination and adjustment	C3PL, T4PL, T5PL, T7PL, Sacral 2PL, Sphenoid minor restriction on left.	Div., Cr	Milestones Current

**Note:** In the spine, all adjustments given were low amplitude, short lever thrusts with specific lines of drive. Cranial adjustments were given with non-force techniques.<sup>20,23,24</sup>

**Table 4. Services and outcomes.**

strated a more symmetric and proficient commando crawl as his primary means of locomotion (*Table 4*). Hands and knees, cross crawling still required some assistance.

By day 21 following initial presentation, on his 6th visit (*Table 4*), the mother stated that, “He sits great now. He gets into a proper crawl stance but then drops to his elbows to actually crawl. He is having bowel movements

daily and does high five’s.” During the adjustments this day, there was significant release of the sphenoid, temporal, and occipital articulations.

On his 7th and final corrective phase visit (*Table 4*), 23 days following initial presentation, the developmental milestones of head and arm use while prone, sitting unsupported, and crawling were observed as expected for the

infant's age and there were no detectable abnormalities of his primitive and postural reflexes. No spinal subluxations were found on examination, but the sphenoid, temporal bones and right occipital bone demonstrated restriction of motion and required minor adjustments (*Table 4*) using the techniques taught by Carol Phillips.<sup>23</sup>

## Follow-up

The infant was seen for a follow-up visit 6.5 months later, at the age of 15 months. He demonstrated walking and the mother reported that he also ran, played hide-and-seek, and held his own sippy cup. He frequently assisted the mother by cleaning up his toys and books. The mother denied any developmental concerns at this time. After evaluating him for subluxations (*Table 4*), the infant was adjusted in the mid cervical, mid thoracic, and upper sacral areas using the Diversified and SOT techniques described. The cranial technique taught by Carol Phillips<sup>23</sup> was used for a minor sphenoid restriction on the left.

## Discussion

Upon first observation of this eight month old infant, his difficulty sitting and supporting his upper body while prone, and his belly crawling, predominately using his left arm and foot with little use of the right, caused concern.

These concerns may have been dismissed as usual for an infant who had spent too much time in a carrier or containment device and not enough on the floor developing his strength; however, the history provided by the mother, observations of her behavior with the infant and later, her compliance with the home therapy program ruled out this assumption.

The World Health Organization (WHO) findings of 2004, which extended the age range of developmental milestones, could also result in a decision to wait and observe. Because the findings included the infant's lack of progress<sup>22</sup> after crawling for one month, three retained primitive reflexes, and one delayed postural reflex, concerns could not be dismissed. The formation of a differential diagnosis list and immediate chiropractic intervention were indicated.

Some studies suggest that meeting milestones late in these extended ranges may indicate potential complications in the older child and adult including: nocturnal enuresis past the age of 5 years,<sup>3</sup> early onset of autism symptoms,<sup>4</sup> cerebral palsies,<sup>6-8</sup> chronic brain diseases such as schizophrenia,<sup>6</sup> developmental retardation,<sup>8</sup> and school age anxiety and depression.<sup>9</sup>

The findings of Piek<sup>13</sup> and Murray<sup>11,12</sup> also suggests a relationship between early gross motor and later school-aged cognitive development especially in working memory and processing speed<sup>13</sup> and aspects of executive function.<sup>11,12</sup> When an infant learns to crawl, they develop more flexible memory retrieval. Before crawling, an infant's memory retrieval is very specific in nature. Even the change of an object in a hanging mobile or of the scent in a room can reduce memory retrieval in the non-crawling infant.<sup>25</sup> During the first year of life, the brain is undergoing massive dendritic growth and pruning in a "use it or lose it" fashion.<sup>26</sup> Perhaps, the earlier an infant develops the motor milestones that lead to crawling and the earlier that he begins crawling, the better the dendrite paths of memory are established. When crawling is delayed, early intervention may be necessary to help build these pathways.

Chiropractic spinal adjustments normalize joint function, which then optimize afferent information received by the central nervous system (CNS) from the periphery through joint mechanoreceptor stimulation and efferent information relayed from the CNS back to the periphery.<sup>10</sup> If the chiropractic adjustment helps to improve input to the cerebellum, the vestibular system and in turn to the sensory and motor cortices, then the higher cortical centers will be able to better integrate this sensory input and motor output so the infant can better engage with and adapt to his environment. This will then lead to improved motor development, cognitive function and social interaction. The purpose of chiropractic cranial adjustments is to "first, improve the patient's level of wellness by restoring optimum cranial motion encouraging cerebrospinal fluid physiology and, second, by restoring balance to the reciprocal membranous tension within the cranial system, thus improving neurologic functions." There are also 5 very specific goals: 1) To reduce articular restrictions; 2) To reduce membranous restriction patterns; 3) To improve circulation; 4) To reduce potential for neural entrapment from exit foramen in the cranial base; and 5) To increase the vitality of the cranial rhythmic impulse.<sup>23</sup> In this case, the interventions of exercise and chiropractic spinal and cranial adjustments provided the catalyst for rapid normalization of the infant's reflexes and developmental milestones.

## Conclusions

The observable goals of treatment for the infant in this case were to improve his motor planning, muscle strength and endurance so he could sit with and without support, proficiently belly crawl, hands and knees crawl, and progress through the remaining developmental milestones early in their normal ranges. Testable goals included the extinction

of the retained primitive reflexes and strengthening of the Landau postural reflex. These goals were accomplished through chiropractic adjustments of the spine, cranium, and extremity joints and an in-home exercise program carried out by the parents.

Infants with certain delayed milestones and retained infantile reflexes may benefit from chiropractic spinal, cranial and extremity joint adjustments, and rehabilitation exercises. Further studies assessing this benefit need to be designed and executed to determine if Chiropractic adjustments should be included in intervention programs designed to correct these abnormal signs and thus help to reduce the incidence or severity of certain disorders.

## References

1. Carruth BR, Skinner JD. Feeding behaviors and other motor development in healthy children (2-24 months). *J Am Coll Nutr* 2002 Apr;21(2):88-96.
2. Adolph KE. Learning to Move. *Curr Dir Psychol Sci* 2008 June 28; 17(3): 213-218.
3. Touchette E, Petit D, Paquet J, Tremblay RE, Boivin M, Montplaisir JY. Bed-wetting and its association with developmental milestones in early childhood. *Arch Pediatr Adolesc Med* 2005 Dec;159(12):1129-34.
4. Teitelbaum P, Teitelbaum O, Nye J, Fryman J, Maurer RG. Movement analysis in infancy may be useful for early diagnosis of autism. *Proc Natl Acad Sci USA* 1998 Nov 10; 95(23):13982-7.
5. Teitelbaum O, Benton T, Shah PK, Prince A, Kelly JL, Teitelbaum P. Eshkol-Wachman movement notation in diagnosis: the early detection of Asperger's syndrome. *Proc Natl Acad Sci USA* 2004 Aug 10;101(32):11909-14.
6. Paine RS, Brazelton TB, Donovan DE, Drorbaugh JE, Hubbell JP, and Sears EM. Evolution of postural reflexes in normal infants and in the presence of chronic brain syndromes. *Neurology* 1964 Nov;14:1036-48.
7. Allen MC, Alexander GR. Using motor milestones as a multistep process to screen preterm infants for cerebral palsy. *Dev Med Child Neurol* 1997 Jan; 39(1):12-6.
8. Zafeiriou DI. Primitive reflexes and postural reactions in the neurodevelopmental examination. *Pediatr Neurol* 2004 Jul; 31(1):1-8.
9. Piek JP, Barrett NC, Smith LM, Rigoli D, Gasson N. Do motor skills in infancy and early childhood predict anxious and depressive symptomatology at school age? *Hum Mov Sci* 2010 Oct; 29(5):777-86.
10. Vallone S. The role of subluxation in sensory integration dysfunction and the effect of the chiropractic adjustment: A case series. *J Clin Chiropr Pediatr* 2006(7:1) 469-479.
11. Murray GK, Veijola J, Moilanen K, Miettunen J, Glahn DC, Cannon TD, Jones PB, Isohanni M. Infant motor development is associated with adult cognitive categorisation in a longitudinal birth cohort study. *J Child Psychol Psychiatry* 2006 Jan;47 (1):25-9.
12. Murray GK, Jones PB, Moilanen K, Veijola J, Miettunen J, Cannon TD, Isohanni M. Infant motor development and adult cognitive functions in schizophrenia. *Schizophr Res* 2006 Jan 1;81(1):65-74.
13. Piek JP, Dawson L, Smith LM, Gasson N. The role of early fine and gross motor development on later motor and cognitive ability. *Hum Mov Sci* 2008 Oct; 27(5):668-81.
14. Foster JA, Anrig CA The Prenatal and Perinatal Period. In Anrig, C. A. & Plaugher, G. Editors. *Pediatric Chiropractic* (75-161). Baltimore:Williams & Wilkins; 1998.
15. Fysh PN. Chiropractic Care for the Pediatric Patient (1st ed). Arlington: International Chiropractors Association Council on Chiropractic Pediatrics; 2002.
16. University of Utah Health Sciences Library [homepage on the Internet]. Salt Lake City: [updated 2011 Aug 18; cited 2011 Aug 12]. [http://library.med.utah.edu/pedineurologicexam/html/video\\_window.html?vidurl=../movies/newborn\\_n\\_24\\_x2.mov&vidwidth=640&vidheight=480](http://library.med.utah.edu/pedineurologicexam/html/video_window.html?vidurl=../movies/newborn_n_24_x2.mov&vidwidth=640&vidheight=480)
17. University of Utah Health Sciences Library [homepage on the Internet]. Salt Lake City: [updated 2011 Aug 18; cited 2011 Aug 12]. [http://library.med.utah.edu/pedineurologicexam/html/video\\_window.html?vidurl=../movies/06mo\\_12.mov&vidwidth=320&vidheight=240](http://library.med.utah.edu/pedineurologicexam/html/video_window.html?vidurl=../movies/06mo_12.mov&vidwidth=320&vidheight=240)
18. Tanaka, ST, Martin CJ. Clinical Neurology. In Anrig, C. A. & Plaugher, G. Editors. *Pediatric Chiropractic* (479-611). Baltimore:Williams & Wilkins; 1998.
19. Barham-Floreani J. Well Adjusted Babies. 2nd ed. Vitality Prod. Pty Ltd; 2009.
20. Dobson J. Baby Beautiful: A Handbook of Baby Head Shaping. Incline Village: Heirs Press; 1994.
21. Wijnhoven TM, de Onis M, Onyango AW, Wang T, Bjoerneboe GE, Bhandari N, Lartey A, al Rashidi B. Assessment of gross motor development in the WHO Multicentre Growth Reference Study. *Food Nutr Bull* 2004 Mar; 25(1 Suppl):S37-45.
22. Adolph KE, Vereijken B, Denny MA. Learning to crawl. *Child Dev* 1998 Oct; 69(5):1299-312.
23. Phillips CJ. Craniosacral Therapy. In Anrig, CA & Plaugher G, Editors. *Pediatric Chiropractic* (424-454). Baltimore:Williams & Wilkins; 1998.
24. De Jarnette MB. Cranial Technique 1979-1980. Nebraska City: De Jarnette, 1979.
25. Herbert J, Gross J, Hayne H. Crawling is associated with more flexible memory retrieval by 9-month-old infants. *Dev Sci* 2007 Mar;10(2):183-9.
26. Video: PBS. The secret life of the brain. Episode 1. The Baby's Brain. A David Grubin Production.





# Effects of Chiropractic Treatment in a 10-Year-Old Female Suffering from Chronic Constipation

Nancy Mayrand, DC

## ABSTRACT

**Objective:** Discuss the chiropractic management of a pediatric patient suffering from chronic constipation

**Clinical features:** 10-year-old female with chronic constipation since the age of 3 without apparent cause. Bowel movement happens every 2 to 3 days with significant pain and large diameter stool. Current treatment consists of positive reinforcement, which has not been effective.

**Intervention and outcomes:** The patient received 4 full spine diversified and Thompson adjustment over a period of one month. At the end of care, she had a daily bowel movement without pain and normal in size. Follow-up a year later revealed normal bowel habits.

**Conclusion:** This case suggests chiropractic care may be effective and safe for treating chronic constipation in pediatric patient.

**Keywords:** constipation, treatment, chiropractic, pediatric

## Introduction

Constipation is a common condition among the pediatric population. It has been reported that approximately 3% of general pediatric patient visits and 25% of consultation to a pediatric gastroenterologists are related to infrequent bowel movements.<sup>1</sup> Difficulties related to elimination are often accompanied by pain, fear and avoidance, which can aggravate the problem.<sup>2</sup> Causes are numerous, such as diet (insufficient fluid intake, insufficient fiber intake and diet high in constipation-causing foods), change in physical activity, anal fissures, and psychological factors.<sup>3</sup> Metabolic, congenital and neurological disorders and also drugs may cause constipation as well.<sup>4</sup> Signs and symptoms related to this condition are abdominal pain, nausea, poor appetite, cranky behavior, sensation of incomplete evacuation, bleeding and clay-like stool in the child's underwear.<sup>5</sup>

The definition of constipation in the literature often differs from that of general perception of the population. In the literature, constipation is diagnosed on the basis of the symptoms and bowel movement frequency.<sup>6</sup> Diagnosis is based on three criteria: stool consistency, ease of bowel movement and frequency.<sup>3</sup> Constipation is considered present if the patient reports fewer than three stools per week, more than 25% of the time associated with straining, and incomplete evacuation or pellet-like feces.

Several treatment alternatives are accepted in medicine for constipation such as dietary fiber, biofeedback, fluid intake and laxatives. Despite these measures, many patients do not respond and continue to have long term problems.<sup>7</sup> Studies have shown that one year after the initial diagnosis, 30 to 50% of children continue to have symptoms.<sup>8</sup> The use of complementary and alternative medicine (CAM) is growing in popularity. Chiropractic is the most popular CAM for children. Prevalence of consultation for functional constipation ranges from 0.7% to 29.6% with a median of 8.9% for chiropractic care.<sup>2</sup> Research on Pub Med and index to chiropractic literature with chiropractic and constipation for key words revealed a few case reports and a review of literature have been done on the effect of chiropractic on chronic constipation.

In the present study, the case history, chiropractic management and clinical outcomes in a 10 year-old female patient with chronic constipation are reported.

## Case Report

A 10-year-old Caucasian female, accompanied by her mother, had a history of chronic constipation. Her mother reported that the condition began when she was around 3 years old with no apparent cause. Bowel movement happens every 2 to 3 days, but the patient is straining and reports feeling significant pain during fecal passing. Two out of three times, the parents need to unclog the toilet because the stools were hard and large in diameter. Eating white bread seems to aggravate the problem. Previous treatment consisted of 1 spoon of mineral oil daily,

*Nancy Mayrand, DC*

*Private practice: Bécancour, Québec, Canada*

*Email: nmayrand@hotmail.com*

but the patient had difficulty in retaining herself and was soiling her underwear. Current intervention of the parents was positive reinforcement when the child was having a bowel movement. Health history revealed that from 14 months to 7 years of age, the patient suffered from growth retardation and was given Pediasure. She also suffered from infantile migraines. Finally, her mother reported that it was difficult and lengthy process to toilet train the child.

Physical examination revealed normal vital signs. Standing postural evaluation showed a high right iliac crest and a left low shoulder. Lumbar range of motion was normal while cervical range of motion revealed non-painful restriction into left lateral flexion. Deep-tendon reflexes were normal. Leg length findings using Thompson analysis showed a left short leg associated with a positive Derefild. Static and motion palpation of the spine revealed restricted joint motion of C2 on the right, L5 on the right, a posterior ilia (as palpated by using the posterior superior iliac spine as a landmark) on the left and a rotated sacrum also on the left.

A diagnosis of multiple vertebral subluxation complexes associated with constipation was made. Treatment was initiated right after the initial evaluation. The patient was adjusted full spine using high velocity low amplitude manipulation (diversified technique) for C2 and L5. Drop adjustments according to Thompson technique were performed for the pelvis and the sacrum. The patient underwent a total of four visits within a month. Treatment outcomes and results are noted in *Table 1*. The patient reported no adverse reaction to any of the treatments rendered.

A follow up call made a year later revealed that the patient was having a bowel movement every two days, without pain or straining. Size in diameter was normal.

## Discussion

Functional constipation is due to a slow intestinal transit, leading to increased water absorption by the colon.<sup>2</sup> There are two major hypotheses in the literature about the relation of vertebral subluxation and bowel movement, both related to the autonomic innervation of the intestine.

The sympathetic stimulation of the large intestine inhibits gastrointestinal activity by decreasing smooth muscle tone and motility and increasing the contraction the sphincter. Innervation of the first two-thirds of the colon is carried by thoracic splanchnic nerves (T10-T11), while

Date	Level adjusted	Bowel movement
03/02	C2, L5, SI joint and sacrum	Once every 2-3 days, significant pain, straining, large size
03/10	T6, L5, SI joint	almost every day, no pain, little straining
03/17	T4, L5, sacrum	Every day except once, no pain, little straining, normal size
03/31	C2, T4, L5, SI joint	Every day, no pain, no straining, normal size

**Table 1. Summary of treatment and bowel habit**

the last third of the colon, the sigmoid colon, the rectum and anus are innervated by lumbar splanchnic nerves. Both thoracic and lumbar splanchnic nerves carry preganglionic fibers, which synapse in pre-vertebral ganglia associated with celiac, inferior and superior mesenteric and inferior and superior hypogastric plexuses. Then, postganglionic fibers pass to the viscera.<sup>9,10</sup>

On the other hand, parasympathetic stimulation increases smooth muscle tone, motility and relaxation of the sphincter, leading to increased gastrointestinal activity. Preganglionic parasympathetic fibers are carried by the vagus nerve for the first two-thirds of the colon. Innervation of the last part of the large intestine, rectum and sphincter arise from pelvic splanchnic nerves (S2-S4). Preganglionic fibers synapse in the enteric ganglia located directly in the wall of the viscera. Parasympathetic innervation is abundant in this region compared to other parts of the gut related to its evacuation function.<sup>11</sup>

The first hypothesis is based upon the segmental facilitation theory by Korr,<sup>12</sup> stating that somatic dysfunction may affect the functioning of a viscera innervated by the same segmental levels. This study is supported by the work of Sato.<sup>13</sup> Using a rat model, he demonstrated that pinching abdominal skin increased sympathetic activation and reducing gastric motility. This lends a strong support to the concept of somatovisceral reflex related to the vertebral subluxation.

The second hypothesis is based upon the model of Kent<sup>14</sup> and Seaman<sup>15</sup> on the link between vertebral subluxation and the increased stress/sympathetic activity. Restricted joint motion decreases firing of mechanoreceptor axons and increases firing of nociceptive axons. Nociceptive stimulation affects preganglionic sympathetic neurons and dorsal, anterior and anterolateral horn interneurons. As muscle spindles are also innervated by those sympathetic

fibers, positive static palpation may correlate with increased sympathetic activity at this level. Nociception stimulation also reaches the hypothalamus, a neuroendocrine control center. This leads to secretion of catecholamines such as corticotrophin-releasing factor (CRF) and cortisol. This simulates a chronic increase in stress, leading to decreased gastrointestinal function.

In the present case, the presence of vertebral subluxation at both L5 and the pelvic region may have thrown off the equilibrium between sympathetic and parasympathetic innervations. Based on Korr and Sato hypothesis, the joint restriction at L5 may have increased sympathetic activity, leading to a slower intestinal transit and a difficult elimination. By restoring normal joint motion, the autonomic nervous system may have had the opportunity to return to a state of balance between the sympathetic and parasympathetic systems and bowel movement became normal. Also, according to Kent and Seaman, the restoration of motion increased mechanoreception and decreased nociception, interruption of the cascade effects leading to increased sympathetic activity, resulting in a shift towards more normal bowel habits.

Regarding the patient's condition post treatment, one year, a slight regression of the symptoms was noted on the basis of the frequency of the bowel movement. This regression could possibly have been avoided by extending the treatment plan for a period of several additional months on a monthly basis. After the treatment series, it was suggested to the mother to continue care (a visit a month) to ensure that there was adequate time for maturation of the plastic neuronal changes initiated with the initial treatment. The mother was satisfied with treatment outcome and chose not to continue with the additional recommended care. Future studies could incorporate this aspect as well as considering the influence of other environmental aspects (hydration, diet, exercise, stress) into the research model on a larger cohort.

## Conclusion

Due to patient's favorable response to treatment without any adverse effect, this case report suggests that chiro-

practic may be safe and effective to treat chronic functional constipation. However, more studies on a larger cohort could bring more comprehension and stronger evidence of the effect of chiropractic adjustments on physiology and viscera function.

## References

1. Evaluation and treatment of constipation in infants and children: recommendation of the North American Society for pediatric gastroenterology, hepatology and nutrition. *J Pediatr Gastroenterol Nutr* 2006; 43: e1-e13.
2. Alcantara J and Mayer DM. The successful chiropractic care of pediatric patients with chronic constipation: a case series and selective review of literature. *Clinical Chiropractic* 2008; 11:138-147.
3. Holbrook B. Chiropractic treatment of childhood constipation: a review of literature. *J Clin Chiropractic Pediatr* 2005; 6(3): 427-431.
4. Wald A. Diagnosis of constipation in primary and secondary care. *Rev Gastroenterol disorders* 2004; 4 s28-s33.
5. Parnell C and Nekoomand A. Improvement of chronic constipation in a 5-year-old female after chiropractic treatment. *J Clin Chiropractic Pediatr* 2011; 12(2): 924-6.
6. Redly M. The effect of chiropractic care on a patient with chronic constipation. *J Can Chiropr Assoc* 2001; 45(3): 185-191.
7. Horkey M. Resolution of chronic constipation and neck pain following chiropractic care in a 6-year-old female. *J Pediatric, Maternal & Family Health* 2010; may 10: 51-5.
8. Quist DM and Duray SM. Resolution of symptoms of chronic constipation in a 8-year-old male after chiropractic treatment. *JMPT* 2007; 30(1): 65-8.
9. Moore KL, Dalley AF. Clinically oriented Anatomy. 5th ed. Philadelphia: Lippincott, William and Wilkins; 2006.
10. Gray's Anatomy: the anatomical basis of clinical practice. 39th ed. London: Elsevier; 2005.
11. Guyton AC, Hall JE. Textbook of medical physiology. 11th ed. Philadelphia: Elsevier Saunders; 2006.
12. Korr I. The spinal cord as organizer of disease processes: some preliminary perspectives. *J Am Osteopath Assoc* 1976; 76: 35-45.
13. Sato A. Somatovisceral reflexes. *JMPT* 1995; 18:597-602.
14. Kent C. Models of vertebral subluxation: a review. *J Vertebral Subluxation Res.* 1996; 1(1): 19-28.
15. Seaman DR and Winterstein JF. Dyafferentation: a novel term to describe the neuropathophysiological effects of joint complex dysfunction. A look at likely mechanism of symptom generation. *JMPT* 1997; 21(4): 267-280.



# Management of a 9-Year-Old Male with Encopresis and Chronic Constipation

Jennifer Brocker, DC and C.J. Woslanger, DC

## ABSTRACT

**Objective:** To discuss the case of a 9-year-old boy with chronic constipation and encopresis who was co-managed by multiple providers, including chiropractic care.

**Clinical Report:** A 9-year-boy sought care for a life long history of constipation and recent episodes of encopresis. His past medical history was non-contributory. A health history and physical exam, in addition to ultrasound and radiography ruled out organic causes of the constipation and encopresis.

**Intervention and Outcome:** Interventions included chiropractic adjustments that were performed using high velocity, low amplitude diversified techniques and Craniosacral Therapy (Upledger Protocol). Naturopathic physician managed the patient with supplements, and a psychological referral was made. Nine months after beginning treatment, the patient reported having improved bowel movements and reduced incidents of encopresis. Furthermore, he experienced a significant reduction in his daily use of MiraLax.

**Conclusion:** Chiropractic care, with co-management from other health professionals, reduced the episodes of constipation and encopresis for this patient. Controlled studies are warranted to determine the effectiveness of chiropractic management of pediatric constipation and encopresis.

## Introduction

Pediatric constipation is considered present if a patient has two or more of the following in the prior 8-weeks:<sup>1</sup>

- fewer than 3 bowel movements per week
- more than 1 episode of fecal incontinence per week
- retentive posturing and withholding behavior
- large stools in the rectum
- stools that obstruct the toilet
- painful defecation

Occasionally associated with chronic constipation is encopresis, also known as fecal incontinence. Encopresis is the passage of stools in inappropriate places.<sup>1</sup> In the United States, the prevalence of constipation and fecal incontinence in the pediatric population is 22.6% and 4.4%, respectively.<sup>2</sup>

It is estimated that 95% of children who have constipation have no organic cause of the symptoms.<sup>3</sup> However, experts suspect that fear from a previous large stool, hard

or painful stools, or anal fissures result in retentive posturing leading to constipation.<sup>3,9</sup> The withholding behavior eventually causes a habituation of bowel and rectal neurons to the presence of fecal matter; thus, allowing further accumulation of fecal material in the colon.<sup>4-8</sup>

Encopresis may occur because watery stools seep around the large fecal mass.<sup>5,7,8</sup> Other causes of constipation and encopresis may be inappropriate functioning of the autonomic nervous system when defecating, behavioral problems, stressors, and toilet training.<sup>4,6-10</sup>

Management of this condition is challenging for health care professionals because the pathophysiology is often multifactorial. Typical treatment regimens include laxatives, behavioral therapy, diet, and education.<sup>3-7,11</sup> However, integrative management with complementary and alternative medicine (CAM) providers has received attention as a holistic approach to managing childhood constipation and encopresis.<sup>7</sup>

In a 2007 National Health Statistics Report, 11.8% of children in the United States used a CAM therapy in the previous 12 months.<sup>12</sup> In addition, the second most commonly used CAM therapy was chiropractic or osteopathic manipulation (2.8%).<sup>12</sup> Within the chiropractic profession, 7.7% of chiropractors see patients 5 years old or younger, and 9.4% see patients 6 to 17 years of age.<sup>13</sup> It is not known how often chiropractors encounter constipation

---

**Jennifer Brocker, DC**

Associate clinician, Portland Chiropractic Group, Portland, Oregon  
Email: drjenny@portlandchiropracticgroup.com

**C.J. Woslanger, DC**

Clinical research fellow at Palmer Center for  
Chiropractic Research, Palmer College of Chiropractic,  
Davenport, Iowa



or encopresis, but given their prevalence, it is likely that chiropractors that care for the pediatric population will have patients with one or both of these conditions.

There is insufficient evidence to suggest that chiropractic care produces a successful outcome for patients with constipation and associated encopresis.<sup>14</sup> To the authors' knowledge, only one case report is found in the literature that discusses management of encopresis with chiropractic care.<sup>15</sup> The case in this report discusses a 9-year-old boy suffering from chronic constipation with associated encopresis that was successfully co-managed, which resulted in a reduction of gastrointestinal complaints. It is hopeful that this report develops interest for chiropractic research in pediatric non-musculoskeletal complaints such as constipation and encopresis.

### Case Presentation

A 9-year-old male from a middle-class blended family was referred for care of chronic constipation with associated encopresis, complicated by secondary diurnal and nocturnal enuresis.

Pertinent patient history included a postnatal history of a finicky and "clingy" infant who nursed every 2 hours. He was born at 41.5 weeks gestation following 14 hours of labor and 2 hours of pushing; his mother reported significant back pain during the labor, though he presented occiput-anterior. His mother reported no physical or developmental abnormalities. The patient had a history of irregular bowel movements. As an infant, he had a bowel movement once every 6-10 days. At the time of his exam, he was having bowel movements once every 1-3 days while on laxatives. The encopresis (unintentional fecal incontinence) started 1 week prior to his initial visit with a progressive increase in frequency and volume. He had a 4-year history of secondary diurnal and nocturnal enuresis, with no precipitating event. His pediatrician and the referring naturopath were managing his conditions. The pediatrician prescribed MiraLax, which he had been taking daily for 3-years. He had been under naturopathic care for 10-months that consisted of vitamin D, vitamin C and supplements (Yeast Aid, Para-Guard, magnesium, and probiotics) to take in addition to the MiraLax. He did not have any dietary restrictions at exam. He had also not undergone any prior diagnostic radiologic evaluations.

The patient's mother reported a very emotionally stressful pregnancy. The source of stress continued post-natally for about 2 years. At which point, his mother remarried,

introducing a new father and stepbrother into the family. A half sister was added a few years later.

Physical exam revealed he was an average height and weight for his age. He had a left short leg (1-inch), a moderate increase in Heel-to-Buttock Test on the left, and a mild anterior rounding of the shoulders; all other orthopedic exams were negative. On examination of the abdomen, a decrease in bowel sounds was noted in the right lower quadrant, but no palpable abnormalities were detected. Motion and static palpation revealed moderate to severe segmental motion restrictions at L4, L5, and the left sacroiliac joint with associated moderate to severe muscular hypertonicity, moderate segmental motion restrictions at T3, T4, T6, and T7, and mild segmental motion restriction at C1. He was referred for abdominal x-ray and ultrasound that revealed no organic cause of his symptoms.

### Interventions and Outcomes

The treatment plan included use of high-velocity, low amplitude (HVLA) spinal adjustments. Side-posture HVLA and diversified techniques were used on the lumbar and sacral spine. Thoracic spine was treated with prone HVLA diversified, double thenar and supine, anterior adjustments. Cervical spine was adjusted using a HVLA supine diversified technique. In addition, Craniosacral Therapy was performed using the Upledger Protocol.<sup>16</sup>

The initial treatment frequency was 2 times per week for 4 weeks, 1 time per week for 8 weeks, 1 time per 2 weeks for 10 weeks. This treatment frequency was based on the number and chronicity of subluxations present. However, frequency of care was adjusted based on his symptoms and objective spinal findings. *Table 1* shows how care was adjusted based on his gastrointestinal symptoms.

There was almost immediate resolution of his enuresis with some regression as treatment continued. These regressions were corrected with the above adjusting protocols. His bowel function began to normalize after 3 weeks of care; he was having more regularity in his bowel movements and less difficulty passing stools. He also saw a decrease in the frequency and volume of incontinence during that time. Three months after his initial visit, Kegel exercises were added to his chiropractic protocol, 10 repetitions 2-3 times per day, to strengthen the pelvic floor musculature and support bowel and bladder control. Concurrently, his naturopath reduced the dosage of MiraLax because of improvement in bowel function. The treatment frequency was tapered to 5 months after his initial visit; however, he did have a brief relapse of both



	Months of Treatment				
	0	3 <sup>b</sup>	5 <sup>c</sup>	6	9 <sup>d</sup>
Frequency of Chiropractic Visits	-	1 visit per week	1 visit per month	1 visit per 2 weeks	1 visit per 2 weeks
Frequency of BM <sup>e</sup>	1 BM every 1-3 days	1-2 BMs every 2 days	1-2 BMs every 2 days	1-2 BMs every 2 days	1 BM every 1-2 days
Frequency of Encopresis	1-2 incidents per day	4-8 incidents per month	8-12 incidents per month	1-2 incidents per month	0-1 incidents per month
MiraLax Dosage <sup>f</sup>	2	1.5	1	1	none

<sup>a</sup> 2,000 mg of vitamin C and 1,000 mg of magnesium were taken throughout the period of care

<sup>b</sup> Patient began kegel exercises: 10 repetitions 2-3 times per day

<sup>c</sup> Patient independently started psychological counseling

<sup>d</sup> Patient started acupuncture

<sup>e</sup> BM = bowel movement(s); the number of bowel movements corresponds to the patients constipation

<sup>f</sup> Dosage as measured by capfuls per day

Table 1. Nine-month time course of gastrointestinal symptoms, and resulting frequency of chiropractic care and prescription usage.<sup>a</sup>

enuresis and encopresis. These relapses were managed with chiropractic care at elevated frequency of visits. In addition, five months into care, he began psychological counseling sessions initiated by the family to address any underlying mental health issues that might be contributing to his symptoms (*see Table 1*).

Nine months after beginning treatment, the child remains under chiropractic and naturopathic care. The frequency of chiropractic care was increased to once every 2 weeks due to a recent relapse of encopresis. It was recommended that he receive acupuncture to continue to address any underlying issues that might be contributing to his inability to maintain long term correction of his subluxations. Nevertheless, this treatment regimen resulted in a decrease in the frequency and volume of fecal soiling accidents and reduced constipation, i.e. increased bowel movements after 9-months of care (*see Table 1*). In addition, he noted reduced diurnal and nocturnal enuresis. Also, he has discontinued taking MiraLax, but continues his prescription of 1,000 mg Magnesium and 2,000 mg vitamin C daily. No adverse events were reported.

Discussion

A biopsychosocial model has been put forth that theorizes the etiology of functional gastrointestinal disorders (FGID) that includes constipation and encopresis. This model incorporates early life factors (i.e. genetics, environment), psychosocial factors (i.e. life stress psychological state, coping, social support), and physiological factors (motility, sensation, inflammation, etc.) that affect the

“brain-gut axis” that ultimately produce FGID.<sup>7,17</sup> The multiple factors that may be involved suggest the need for multiple treatment strategies to manage pediatric constipation and encopresis.

The conventional treatment for pediatric encopresis with constipation can be categorized into four management strategies: education, medication, behavioral management, and diet.

Education of both parents and child are important in the initial treatment of this condition. Parental education should address negative attitudes, reinforce a positive and encouraging attitude, and focus on teaching the family that the fecal soiling (i.e. encopresis) is not purposeful, but is involuntary.<sup>3,4,6,11</sup> Providing information to help both the parents and the child understand the etiology, the reoccurrence of the problem, and treatment plans in order to minimize the stress of the situation is recommended.<sup>3,5-8,11</sup>

Medications are used for children with constipation for disimpaction and maintenance therapy.<sup>3,5-8</sup> Medications can be categorized either by oral or rectal routes. Oral medications tend to be less invasive but there may be concerns with compliance.<sup>3,6</sup> Oral medications include lubricants (mineral oil), laxatives (polyethylene glycol), and stimulants (Senna).<sup>3,5,6,8</sup> Medications administered the rectal route are more invasive and may include enemas and suppositories.<sup>3,5,6</sup>

Behavioral therapy "...involves regular toilet sitting for up to 5 minutes three or four times a day after meals to establish normal bowel habits."<sup>3</sup> In addition, a recent systematic review suggested that the addition of behavioral interventions (e.g. toilet training, incentive scheme, dietary advice) to laxative therapy yield outcomes that are more successful.<sup>18</sup> In some instances, a patient developing social or depressive symptoms warrants psychotherapy referral.<sup>4,6</sup>

Dietary modifications may also help in children with constipation as a maintenance therapy; however, evidence supporting dietary modifications is weak or inconclusive.<sup>3,5-8</sup> Yet, recommending "A balanced diet that includes whole grains, fruits, and vegetables..." is appropriate when managing these conditions.<sup>6</sup>

No empirical trials exist that compare chiropractic care to conventional care for constipation and encopresis, so it is unknown the effectiveness of chiropractic care on these conditions. To the authors' knowledge only one case report discusses management of encopresis.<sup>15</sup> However, the importance of integrating CAM therapies into treatment and maintenance of constipation and encopresis has gained increased attention. This is because CAM therapies "...often provides less-invasive options than traditional biomedical interventions, and can be blended/balanced safely with other necessary treatments."<sup>7</sup> This case report involved management from both allopathic and CAM therapies highlighting the importance of collaborating with other health providers to treat the multiple etiologies of constipation and encopresis. It is important that chiropractic research begin to look not only into pediatric conditions of the musculoskeletal system, but also into non-musculoskeletal conditions in which the pediatric population may be benefited.

## Limitations

This case report contains a sample of one, which cannot be generalized to others. In addition, this patient was co-managed by other health providers, including a naturopath, acupuncturist and psychological counselor, thus various confounders may have contributed to the patient's successful management. In addition, constipation and encopresis may be a reoccurring condition and success of care could be due to the natural history of the condition (i.e. spontaneous remission). Assessment of the results was largely from the parent recalling the success of care introducing interview and recall bias.

## Conclusion

Pediatric patients that suffer from chronic constipation and encopresis are common, and these conditions can be difficult to manage. This is due to the multiple etiologies that are difficult to parse out; therefore, a thorough history and evaluation is necessary. Management of constipation and encopresis usually focuses on alleviating the constipation in hopes that the patient will produce less painful and softer stools that may result in reduced encopresis episodes. Chiropractic care for these conditions has not been evaluated with rigorous scientific methodologies, but there is an increasing interest in CAM therapies on non-musculoskeletal conditions. In this case, chiropractic care and co-management with other health professional helped reduce the patient's encopresis and constipation symptoms without any adverse effects. Research into chiropractic care on non-musculoskeletal conditions needs to begin in order to determine the effectiveness of care on these conditions.

## References

1. Benninga M, Candy DC, Catto-Smith AG, et al. Paris consensus on childhood constipation terminology (PACCT) group. *J Pediatr Gastroenterol Nutr* 2005; 40(3): 273-275.
2. Loening-Baucke V. Prevalence rates for constipation and faecal and urinary incontinence. *Arch Dis Child* 2007; 92(6): 486-489.
3. Pashankar DS. Childhood constipation: evaluation and management. *Clin Colon Rectal Surg* 2005; 18(2): 120-127.
4. van Dijk M, Benninga MA, Grootenhuis MA, et al. Chronic childhood constipation: a review of the literature and the introduction of a protocolized behavioral intervention program. *Patient Educ Couns* 2007; 67(1-2): 63-77.
5. Philichi L. When the going gets tough: pediatric constipation and encopresis. *Gastroenterol Nurs* 2008; 31(2): 121-130.
6. Constipation Guideline Committee of the North American Society for Pediatric Gastroenterology, Hepatology and Nutrition. Evaluation and treatment of constipation in infants and children: recommendations of the North American Society for Pediatric Gastroenterology, Hepatology and Nutrition. *J Pediatr Gastroenterol Nutr* 2006; 43(3): e1-13.
7. Culbert TP, Banez GA. Integrative approaches to childhood constipation and encopresis. *Pediatr Clin North Am* 2007; 54(6): 927-947.
8. Benninga MA, Voskuil WP, Taminiau JA. Childhood constipation: is there new light in the tunnel? *J Pediatr Gastroenterol Nutr* 2004; 39(5): 448-464.
9. Borowitz SM, Cox DJ, Tam A, et al. Precipitants of constipation during early childhood. *J Am Board Fam Pract* 2003; 16(3): 213-218.
10. Raghunath N, Glassman MS, Halata MS, et al. Anorectal motility abnormalities in children with encopresis and chronic constipation. *J Pediatr* 2011; 158(2): 293-296.
11. Dobson P, Rogers J. Assessing and treating faecal incontinence in

- children. *Nurs Stand* 2009; 31(2): 121-130.
12. Barnes PM, Bloom B, Nahin RL. Complementary and alternative medicine use among adults and children: United States, 2007. *Natl Health Stat Report* 2008; 10(12): 1-23.
  13. Christensen MG, Kollasch MW, Hyland JK, et al. Practice analysis of chiropractic 2010. Greely, CO; 2010. <http://www.nbce.org/publication/job-analysis.html#download>
  14. Hawk C, Khorsan R, Lisi AJ, Ferrance RJ, et al. Chiropractic care for nonmusculoskeletal conditions: a systematic review with implications for whole systems research. *J Altern Complement Med* 2007; 13(5): 491-512.
  15. Barber VA, Ring TS. Encopresis: a case study of the response of pediatric fecal incontinence while under chiropractic care. *Top Clin Chiropr* 2002; 9(1): 68-72.
  16. Upledger JE, Vedevoogd JD. Craniosacral therapy. Chicago: Eastland Press; 1983.
  17. Drossman DA. The functional gastrointestinal disorders and the Rome III process. *Gastroenterology* 2006; 130(5): 1377-1390.
  18. Brazzelli M, Griffiths P. Behavioural and cognitive interventions with or without other treatments for the management of faecal incontinence in children. *Cochrane Database Syst Rev* 2006; 19(2).



# Abstracts of Interest

---

**Haque S, Bilal Shafi BB, Kaleem M. Imaging of torticollis in children. *Radiographics* 2012 Mar-Apr; 32(2):557-71.**

**ABSTRACT:** The normal anatomy of the cervical spine and various imaging techniques for the evaluation of torticollis are reviewed, and possible causes of torticollis in infants and children are discussed, with an emphasis on relevant imaging findings. Torticollis is a congenital or acquired deformity characterized by rotational deformity of the cervical spine with secondary tilting of the head. Although torticollis is a sign of an underlying disease process, its presence does not imply a specific diagnosis, and the cause should be sought if torticollis persists or is associated with other symptoms. Congenital torticollis, seen in neonates and infants, usually results from craniocervical vertebral anomalies or muscular causes, although ocular abnormalities such as congenital paralytic squint (strabismus) and congenital nystagmus should also be considered. Acquired torticollis, seen in older children and adolescents, is often secondary to trauma, infection, or tumors. Imaging should be used as a general screening tool only after a complete medical history and clinical findings have been obtained. In newborns or infants with congenital torticollis, ultrasonography (US) is the modality of choice. In cases of acquired torticollis resulting from trauma, conventional radiography (lateral and anteroposterior views) should be the first-line imaging modality. In nontraumatic acquired torticollis, computed tomography (CT) of the neck or cervical spine is the initial imaging study. If CT findings are negative, magnetic resonance (MR) imaging of the brain and cervical spine should be performed. The use of multiple imaging modalities (conventional radiography, US, CT, and MR imaging) is common in the radiologic work-up of torticollis, and radiologists must understand the role of each imaging modality in patients of various ages.

Source: Department of Radiology, Manchester Academic Health Sciences Centre, Royal Manchester Children's Hospital, Oxford Rd, Manchester M13 9WL, England. [sairahaque@doctors.org.uk](mailto:sairahaque@doctors.org.uk)

**Riley M, Bluhm B. High Blood Pressure in Children and Adolescents. *American Family Physician* April 1 2012; 85(7).**

**ABSTRACT:** High blood pressure in children and adolescents is a growing health problem that is often overlooked by physicians. Normal blood pressure values for children and adolescents are based on age, sex, and height, and are available in standardized tables. Prehypertension is

defined as a blood pressure in at least the 90th percentile, but less than the 95th percentile, for age, sex, and height, or a measurement of 120/80 mm Hg or greater. Hypertension is defined as blood pressure in the 95th percentile or greater. A secondary etiology of hypertension is much more likely in children than in adults, with renal parenchymal disease and renovascular disease being the most common. Overweight and obesity are strongly correlated with primary hypertension in children. A history and physical examination are needed for all children with newly diagnosed hypertension to help rule out underlying medical disorders. Children with hypertension should also be screened for other risk factors for cardiovascular disease, including diabetes mellitus and hyperlipidemia, and should be evaluated for target organ damage with a retinal examination and echocardiography. Hypertension in children is treated with lifestyle changes, including weight loss for those who are overweight or obese; a healthy, low-sodium diet; regular physical activity; and avoidance of tobacco and alcohol. Children with symptomatic hypertension, secondary hypertension, target organ damage, diabetes, or persistent hypertension despite nonpharmacologic measures should be treated with antihypertensive medications. Thiazide diuretics, angiotensin-converting enzyme inhibitors, angiotensin II receptor blockers, beta blockers, and calcium channel blockers are safe, effective, and well tolerated in children.

**Mordecai SC, Dabke HV. Efficacy of exercise therapy for the treatment of adolescent idiopathic scoliosis: a review of the literature. *Eur Spine J* 2012 Mar; 21(3):382-9. Epub 2011 Nov 8.**

**PURPOSE:** Current evidence regarding the use of exercise therapy in the treatment of adolescent idiopathic scoliosis (AIS) was assessed with a review of published literature. **METHODS:** An extensive literature search was carried out with commonly used medical databases. A total of 155 papers were identified out of which only 12 papers were deemed to be relevant. **RESULTS:** There were nine prospective cohort studies, two retrospective studies and one case series. All studies endorsed the role of exercise therapy in AIS but several shortcomings were identified — lack of clarity of patient recruitment and in the method of assessment of curve magnitude, poor record of compliance, and lack of outcome scores. Many studies reported "significant" changes in the Cobb angle after treatment, which were actually of small magnitude and did not take into account



the reported inter or intra-observer error rate. All studies had poor statistical analysis and did not report whether the small improvements noted were maintained in the long term. **CONCLUSIONS:** This unbiased literature review has revealed poor quality evidence supporting the use of exercise therapy in the treatment of AIS. Well-designed randomised controlled studies are required to assess the role of exercise therapy in AIS.

Source: Department of Trauma and Orthopaedics, Salisbury NHS Foundation Trust, Salisbury District Hospital, Salisbury, Wiltshire, SP2 8BJ, UK. *Simon\_mordecai@yahoo.com*

**Rucklidge JJ, Harrison R, Johnstone J. Can micronutrients improve neurocognitive functioning in adults with ADHD and severe mood dysregulation? A pilot study. *J Altern Complement Med* 2011 Dec;17(12):1125-31. Epub 2011 Nov 23.**

**OBJECTIVES:** Little research has investigated how micronutrients (minerals and vitamins) affect cognitive functioning, despite preliminary studies showing they may improve psychiatric functioning. **INTERVENTION:** This pilot study investigated the impact of a 36-ingredient micronutrient formula consisting mainly of vitamins and minerals on neurocognitive functioning in 14 adults with attention-deficit/hyperactivity disorder (ADHD) and severe mood dysregulation. **DESIGN:** The formula was consumed in an open-label trial over an 8-week period. **OUTCOME MEASURES:** The participants completed tests of memory (Wide Range Assessment of Memory and Learning) and executive functioning (Delis-Kaplan Executive Functioning System and Conners Continuous Performance Test) at baseline and at the end of the trial. A gender- and age-matched control group of 14 non-ADHD adults not taking the formula were assessed on the same tests 8 weeks apart in order to investigate the impact of practice on the results. **RESULTS:** There were no group differences in ethnicity, socio-economic status and estimated IQ. Significant improvement was observed in the ADHD group, but not the control group, across a range of verbal abilities including verbal learning, verbal cognitive flexibility and fluency, and verbal inhibition. These neurocognitive improvements were large and consistent with improved psychiatric functioning. No changes were noted above a practice effect in visual-spatial memory and there were no improvements noted in reaction time, working memory, or rapid naming for either group. **CONCLUSIONS:** Although the pilot and open-label design of the study limits the generalizability of the results, it supports a growing body of literature recognizing the importance of nutrients for mental health and cognition. The results

also provide evidence supporting the need for randomized clinical trials of micronutrients as well as other experimental studies in order to better assess whether improved neurocognitive functioning may contribute to improved psychiatric symptoms.

Source: Department of Psychology, University of Canterbury, Christchurch, New Zealand. *julia.rucklidge@canterbury.ac.nz*

**Gale C, Logan KM, Santhakumaran S, Parkinson JR, Hyde MJ, Modi N. Effect of breastfeeding compared with formula feeding on infant body composition: a systematic review and meta-analysis. *Am J Clin Nutr* 2012 Mar;95(3):656-69. Epub 2012 Feb 1.**

**BACKGROUND:** Early-life nutrition may influence later body composition. The effect of breastfeeding and formula feeding on infant body composition is uncertain. **OBJECTIVE:** We conducted a systematic review and meta-analysis of studies that examined body composition in healthy, term infants in relation to breastfeeding or formula feeding. **DESIGN:** PubMed was searched for human studies that reported the outcomes fat-free mass, fat mass, or the percentage of fat mass in breastfed and formula-fed infants. Bibliographies were hand searched, and authors were contacted for additional data. The quality of studies was assessed. Differences in outcomes between feeding groups were compared at prespecified ages by using fixed-effects analyses except when heterogeneity indicated the use of random-effects analyses. **RESULTS:** We identified 15 studies for inclusion in the systematic review and 11 studies for inclusion in the meta-analysis. In formula-fed infants, fat-free mass was higher at 3-4 mo [mean difference (95% CI): 0.13 kg (0.03, 0.23 kg)], 8-9 mo [0.29 kg (0.09, 0.49 kg)], and 12 mo [0.30 kg (0.13, 0.48 kg)], and fat mass was lower at 3-4 mo [-0.09 kg (-0.18, -0.01 kg)] and 6 mo [-0.18 kg (-0.34, -0.01 kg)] than in breastfed infants. Conversely, at 12 mo, fat mass was higher in formula-fed infants [0.29 kg (-0.03, 0.61 kg)] than in breastfed infants. **CONCLUSION:** Compared with breastfeeding, formula feeding is associated with altered body composition in infancy.

Source: Section of Neonatal Medicine, Chelsea & Westminster Hospital Campus, Imperial College London, London, United Kingdom.

**Zuvekas SH, Vitiello B. Stimulant medication use in children: a 12-year perspective. *Am J Psychiatry* 2012; 169(2):160-6 (ISSN: 1535-7228).**

**OBJECTIVE:** The authors examined the utilization of stimulant medications for the treatment of ADHD in U.S.



children during the period 1996-2008 to determine trends by age, sex, race/ethnicity, family income, and geographic region. **METHOD:** The 1996-2008 database of the Medical Expenditure Panel Survey, a nationally representative annual survey of U.S. households, was analyzed for therapeutic stimulant use in children age 18 and younger. The data for 1987 were also recalculated for reference. **RESULTS:** An estimated 3.5% (95% confidence interval=3.0-4.1) of U.S. children received stimulant medication in 2008, up from 2.4% in 1996. Over the period 1996-2008, stimulant use increased consistently at an overall annual growth rate of 3.4%. Use increased in adolescents (annual growth, 6.5%), but it did not significantly change in 6- to 12-year-olds, and it decreased in preschoolers. Use remained higher in boys than in girls, and it remained consistently lower in the West than in other U.S. regions. While differences by family income have disappeared over time, use of stimulants in ADHD treatment is significantly lower in racial/ethnic minorities. **CONCLUSIONS:** Overall, pediatric stimulant use has been slowly but steadily increasing since 1996, primarily as a result of greater use in adolescents. Use in preschoolers remains low and has declined over time. Important variations related to racial/ethnic background and geographic region persist, thus indicating a substantial heterogeneity in the approach to the treatment of ADHD in U.S. communities.

Source: Center for Financing, Access, and Cost Trends, Agency for Healthcare Research and Quality, Rockville, MD, USA.

**Vitiello B; Elliott GR; Swanson JM; Arnold LE; Hechtman L; Abikoff H; Molina BS; Wells K; Wigal T; Jensen PS; Greenhill LL; Kaltman JR; Severe JB; Odbert C; Hur K; Gibbons R. Blood pressure and heart rate over 10 years in the multimodal treatment study of children with ADHD. *Am J Psychiatry* 2012; 169(2):167-77 (ISSN: 1535-7228).**

**OBJECTIVE:** It is unknown whether prolonged childhood exposure to stimulant medication for the treatment of attention deficit hyperactivity disorder (ADHD) increases the risk for developing abnormalities in blood pressure or heart rate. The authors examined the association between stimulant medication and blood pressure and heart rate over 10 years. **METHOD:** A total of 579 children, ages 7-9, were randomly assigned to 14 months of medication treatment, behavioral therapy, the combination of the two, or usual community treatment. The controlled trial was followed by naturalistic treatment with periodic assessments. Blood pressure and heart rate data were first analyzed with linear regression models based on an intent-

to-treat approach, using raw data and the blood pressure categories of prehypertension and hypertension. Currently medicated patients were then compared with never or previously medicated patients. Associations between cumulative stimulant exposure and blood pressure or heart rate were assessed. **RESULTS:** No treatment effect on either systolic or diastolic blood pressure could be detected. Children who were treated with stimulants had a higher heart rate (mean=84.2 bpm [SD=12.4] on medication alone and mean=84.6 bpm [SD=12.2] on medication plus behavioral therapy) than those who were treated with behavioral therapy alone (mean=79.1 bpm [SD=12.0]) or those who received usual community treatment (mean=78.9 bpm [SD=12.9]) at the end of the 14-month controlled trial, but not thereafter. Stimulant medication did not increase the risk for tachycardia, but greater cumulative stimulant exposure was associated with a higher heart rate at years 3 and 8. **CONCLUSIONS:** Stimulant treatment did not increase the risk for prehypertension or hypertension over the 10-year period of observation. However, stimulants had a persistent adrenergic effect on heart rate during treatment.

#### **E. J. Videlock, F. Cremonini. Meta-analysis: probiotics in antibiotic-associated diarrhea.**

**BACKGROUND:** Diarrhoea is a common occurrence in association with antibiotic administration. Earlier studies and meta-analyses have suggested that probiotic administration reduces the incidence of antibiotic-associated diarrhoea (AAD). **AIM:** To estimate the reduction in risk of AAD with administration of probiotics in randomised placebo-controlled trials and to identify factors associated with such reduction. **METHODS:** Meta-analysis of randomised, double-blinded, placebo-controlled trials including patients treated with antibiotics and administered a probiotic for at least the duration of the antibiotic treatment. The outcome was incidence of diarrhoea irrespective of the presence of *Clostridium difficile* or the development of pseudomembranous colitis. Meta-analysis and meta-regression methods were used to synthesise data and to assess influence of: mean age, duration of antibiotics, risk of bias and incidence of diarrhoea in the placebo group on outcomes. Subgroup analyses explored effects of different probiotic species, patient populations and treatment indications. **RESULTS:** A total of 34 studies were included with 4138 patients. The pooled relative risk (RR) for AAD in the probiotic group vs. placebo was 0.53 (95% CI 0.44-0.63), corresponding to a number needed to treat (NNT) of 8 (95% CI 7-11). The preventive effect of probiotics remained significant

when grouped by probiotic species, population age group, relative duration of antibiotics and probiotics, study risk of bias and probiotic administered. The pooled RR for AAD during treatment for *Helicobacter pylori* (*H. pylori*) was 0.37 (95% CI 0.20-0.69), corresponding to a NNT of 5 (95% CI 4-10). **CONCLUSIONS:** This updated meta-analysis confirms earlier results supporting the preventive effects of probiotics in AAD.

Posted: 06/21/2012; Alimentary Pharmacology & Therapeutics. 2012;35(12): 1355-1369. © 2012 Blackwell Publishing

**Stuber KJ, Wynd S, Weis CA. Adverse events from spinal manipulation in the pregnant and postpartum periods: a critical review of the literature. *Chiropr Man Therap* 2012 March 28; 20:8**

**BACKGROUND:** The safety of spinal manipulation during pregnancy and the postpartum periods has been a matter of debate among manual therapists. Spinal manipulative therapy during these periods is a commonly performed intervention as musculoskeletal pain is common in these patients. To date there has not been an evaluation of the literature on this topic exclusively. **METHODS:** A literature search was conducted on PubMed, CINAHL and the Index to Chiropractic Literature along with reference searching for articles published in English and French in the peer-reviewed literature that documented adverse effects of spinal manipulation during either pregnancy or postpartum. Case reports, case series, and any other clinical study designs were deemed acceptable for inclusion, as were systematic reviews. The appropriate Scottish Intercollegiate Guidelines Network (SIGN) tools were used to rate included articles for quality when applicable. **RESULTS:** Five articles identifying adverse events in seven subjects following spinal manipulation were included in this review, along with two systematic reviews. The articles were published between 1978 and 2009. Two articles describing adverse effects from spinal manipulation on two postpartum patients were included, while the remaining three articles on five patients with adverse effects following spinal manipulation were on pregnant patients. Injury severity ranged from minor injury such as increasing pain after treatment that resolved within a few days to more severe injuries including fracture, stroke, and epidural hematoma. SIGN scores of the prospective observational cohort study and systematic reviews indicated acceptable quality. **CONCLUSIONS:** There are only a few reported

cases of adverse events following spinal manipulation during pregnancy and the postpartum period identified in the literature. While improved reporting of such events is required in the future, it may be that such injuries are relatively rare.

Source: Division of Graduate Education and Research, Canadian Memorial Chiropractic College, 6100 Leslie Street, Toronto, ON M2H 3J1, Canada. [kstuber@cmcc.ca](mailto:kstuber@cmcc.ca).

**Ndetan H, Evans MW Jr, Hawk C, Walker C. Chiropractic or osteopathic manipulation for children in the United States: an analysis of data from the 2007 National Health Interview Survey. *J Altern Complement Med* 2012 April; 18(4):347-54. Epub 2012 March 2**

**OBJECTIVES:** The aim of this study was to describe use of chiropractic and/or osteopathic manipulation by children in the United States along with the specific health conditions for which they sought care. **METHODS:** The study was a secondary data analysis of the National Health Interview Survey 2007, Child Alternative Medicine file as well as the Child Core Sample. National population estimates were generated for reported use of chiropractic or osteopathic manipulation (C/OM) by children for specific health conditions. Odds ratios (OR) and 95% confidence intervals (CI) were generated from binary logistic regression models that assessed the likelihood that children of specific characteristics would use this therapy. **RESULTS:** National estimates indicated that 2.3 million children (2.3%) in the United States had used C/OM in 2007. C/OM was the most common complementary and alternative medicine procedure. Children aged 12-18 years were more likely to have seen these providers than were younger age groups (OR=3.4 [95% CI, 2.1-5.5]). Homeopathy (1.2%), massage (1.0), and naturopathy (0.3%) were the next most common procedures. The most common complaints were back and neck pain. Other conditions for which children were seen included other musculoskeletal conditions, sinusitis, allergies, and nonmigraine headaches. Racial categories did not differ significantly regarding use of manipulation, but those children with both mother and father in the household were more likely to have used this form of care (OR=1.7 [95% CI, 1.1-2.6]). **CONCLUSIONS:** C/OM is primarily used for back and neck pain, which is increasing in prevalence in children. Teens are more likely to use it than are younger children.

Source: Parker Research Institute, Dallas, TX, USA.





...for the love of children

# Council on Chiropractic Pediatrics



of the International Chiropractors Association



## A Leader in Chiropractic Pediatric Education Committed to Clinical Excellence

### Programs and opportunities to advance your knowledge and clinical skills

- A recognized specialty postgraduate program — Diplomate in Clinical Chiropractic Pediatrics (DICCP)
- Conferences and seminars with cutting edge learning sessions and expert speakers
- A peer-reviewed pediatrics research journal, the JCCP
- Forums for the presentation of research papers at national and international symposiums
- A support network of colleagues and instructors with varied expertise and years of pediatric practice experience
- And much, much, more



*If you are a family practitioner  
we invite you to join today!*

## Membership Application Form

ICA COUNCIL ON CHIROPRACTIC PEDIATRICS

### Please Print

Doctor's Name \_\_\_\_\_

Office Address \_\_\_\_\_

City \_\_\_\_\_

State/Province/Country \_\_\_\_\_

Zip/Country Code \_\_\_\_\_

Date of Birth \_\_\_\_\_

Phone Number \_\_\_\_\_

Fax Number \_\_\_\_\_

Chiropractic College of Graduation \_\_\_\_\_

Date of Graduation \_\_\_\_\_

Other Degrees/Where obtained \_\_\_\_\_

Email Address \_\_\_\_\_

National/State Chiropractic Association(s) to which you belong:

Chiro. License # \_\_\_\_\_ State \_\_\_\_\_

Chiro. License # \_\_\_\_\_ State \_\_\_\_\_

Chiro. License # \_\_\_\_\_ State \_\_\_\_\_


### Dues:

■ Application fee (one-time assessment) ..... \$ 15.00

■ Dues (\$180 calendar year) ..... \$ \_\_\_\_\_

Prorated dues are \$15 a month. Start with the month you are joining and calculate through till December

**Total \$ \_\_\_\_\_**



Members receive **FREE Horizons** magazine and **Journal of Clinical Chiropractic Pediatrics**.

### Payment by:

☐ Check (US Banks only) ☐ MasterCard/Visa ☐ AmericanExpress

Credit Card # \_\_\_\_\_

Expiration date \_\_\_\_\_ Security Code \_\_\_\_\_

Signature \_\_\_\_\_

### Return Application to:

#### ICA Council on Chiropractic Pediatrics

6400 Arlington Blvd., Suite 800, Falls Church, VA 22042 USA  
or fax to **703-351-7893**



*Everyone is Invited!*



ICA Council on  
Chiropractic Pediatrics  
&  
ACA Council on  
Chiropractic Pediatrics

*Teaming up for  
another exciting  
conference in*

## Colorado Springs

November 9-11, 2012

This program is packed with vital information and practical workshops. Speakers with knowledge and expertise will share with you the most up-to-date information on pediatric and pregnancy care. You will learn clinical protocols, diagnostic procedures, research methods, case management and adjusting techniques that will keep you on the cutting edge of your professional skills as a chiropractic practitioner and help improve patient outcomes.



### *The slate of expert speakers include:*



Terry Yochum  
DC, DACBR

Stephanie Cave  
MD, FAACP, MS

Bill Moreau  
DC, DACESP

Lora Tanis  
DC, DCCP

Elise Hewitt  
DC, CST, DCCP

Cheryl Hawk  
DC, PhD



John Furlong, ND



Carol Phillips, DC



Meghan Van Loon  
PT, DC, DCCP



Sharon Vallone  
DC, FICCP



Amy Watson, DC

Luncheon  
Guest Speaker  
Brigadier General  
Becky Halstead



### *Three ways to register:*

**By fax:** 703-351-7893 or 703-528-5023  
(outside N. America add country code 001)

**By phone:** 1-800-423-4690 or 571-765-7554  
or 703-528-5000 Ext 554

**Online:** [www.icapediatrics.com](http://www.icapediatrics.com)  
[acapedscouncil.org](http://acapedscouncil.org)

*Plan to be there!*

## Welcome our Saturday Luncheon Guest Speaker



**Brigadier General Becky Halstead**  
*A Champion of Chiropractic*

"After 27 years of military service and combat deployments, I know first-hand the importance of a healthy mind and body — chiropractic care significantly improved my health and quality of life. My new MISSION is to share this fact with others."

Ret. Brigadier General Becky Halstead

### CONFERENCE HOURS

Friday, November 9 8:00am-6:00pm  
Saturday, November 10 8:00am-6:00pm  
Sunday, November 11 7:30am-12:30pm

(20 CE credits applied for through  
Palmer College of Chiropractic Continuing  
Education and Events Department.)



### HOTEL RESERVATIONS

#### The Broadmoor

1 Lakeview, Colorado Springs, CO 80906

Group Rate: \$189 single/double  
(inclusive of resort fee)

Reserve by Phone: 1-800-634-7711 or  
719-577-5775  
Identify yourself as with the  
**ICA/ACA Pediatrics  
Conference**

ICA Council on Chiropractic Pediatrics & ACA Council on Chiropractic Pediatrics



# Joint Conference on Chiropractic & Pediatrics



November 9-11, 2012 • The Broadmoor, Colorado Springs, Colorado

(Please print)

### REGISTRATION FORM

Name \_\_\_\_\_  
Address \_\_\_\_\_  
City \_\_\_\_\_ State/Province \_\_\_\_\_  
Zip/Postal Code \_\_\_\_\_ Country \_\_\_\_\_  
Chiropractic College \_\_\_\_\_ Year of graduation \_\_\_\_\_  
Phone Number (include country code/area code) \_\_\_\_\_  
Email (All confirmations will be by email) \_\_\_\_\_

### REGISTRATION FEES

Please check appropriate box:	By 10/01	From 10/02	Amount
<input type="checkbox"/> ICA Pediatrics Council Member	\$379	\$429	
<input type="checkbox"/> ACA Pediatrics Council Member	\$379	\$429	
<input type="checkbox"/> ICA Member (DC)	\$409	\$459	
<input type="checkbox"/> ACA Member (DC)	\$409	\$459	
<input type="checkbox"/> Non ICA/ACA Member (DC)	\$449	\$499	
<input type="checkbox"/> ICA Student Member	\$179	\$229	
<input type="checkbox"/> ACA Student Member	\$179	\$229	
<input type="checkbox"/> CA/Guest (Non DC)	\$269	\$319	

Registration Total: \$

☐ **Saturday Luncheon** is *not* included with your registration. Graduation of 2012 DICCPs will also take place at the luncheon. Please purchase tickets with registration so we have an accurate count for seating.

Adult	\$29.00	x	_____	=
Child (5-16 years)	\$14.00	x	_____	=

Total for tickets \$

**TOTAL FOR REGISTRATION & SATURDAY LUNCH \$**

### PAYMENT

☐ I am paying by check (Please make payable to **Joint Pediatrics Conference**)  
☐ I am paying by credit card: ☐ MasterCard ☐ Visa ☐ American Express

Credit Card Account # \_\_\_\_\_ Expiration Date \_\_\_\_\_

Security Code \_\_\_\_\_

Your signature \_\_\_\_\_ Date \_\_\_\_\_

### 4 WAYS TO REGISTER

**Mail to:** ACA/ICA Joint Pediatrics Conference, 6400 Arlington Boulevard,  
Suite 800, Falls Church, VA 22042 USA

**Fax to:** 703-351-7893 or 703-528-5023 (outside N. America add country code 001)

**Online:** [www.icapediatrics.com](http://www.icapediatrics.com) or [www.acapedscouncil.org](http://www.acapedscouncil.org)

**Phone:** 800-423-4690 (Ext. 554) or 571-675-7554

**Cancellation fees:** 10% of registration if cancelled more than 30 days before event; less than 30 days 15%; no refunds for no shows.  
Cancellations must be in writing, either faxed or emailed.





The ICA Council on  
Chiropractic Pediatrics offers  
you the opportunity to take your  
expertise to the next level with its

## Diplomate in Clinical Chiropractic Pediatrics (DCCP)

A 30-module, 3-year postgraduate program that has established benchmarks in educational and clinical excellence.

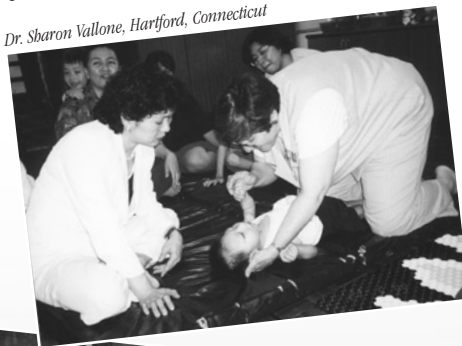The DCCP curriculum is broad-based but comprehensive with a structured syllabus that balances academic knowledge with clinical applications. This specialty program is designed to ensure that the doctor of chiropractic who receives the DCCP credential has the knowledge, competency and skills expected of a DC who is Board certified.

Classes are ongoing in

- Davenport, Iowa (Palmer College campus)
- New Zealand/Australia (administered by the New Zealand College of Chiropractic)
- Montreal, Canada (New class forming for 2013)

*These DCCPs are making a difference.  
You can too!*

*Dr. Sharon Vallone, Hartford, Connecticut*



*Dr. Navine Haworth, Melbourne, Australia*



*Dr. Lora Tanis in Hewitt, New Jersey*

DCCP Board Examinations in 2012-13  
(for Board Eligible candidates only):

- January 13-15, 2012 • Melbourne, Australia
- August 18-19, 2012 • Chicago, Illinois
- June 22-24, 2012 • Montreal, Canada

For more information about the DCCP program visit

**[www.icapediatrics.com](http://www.icapediatrics.com)**

OR EMAIL

**[peditricscouncil@chiropractic.org](mailto:peditricscouncil@chiropractic.org)**

**The ONLY Diplomate Program Endorsed by Both the ICA and ACA Pediatric Councils.**



JOURNAL OF CLINICAL CHIROPRACTIC PEDIATRICS